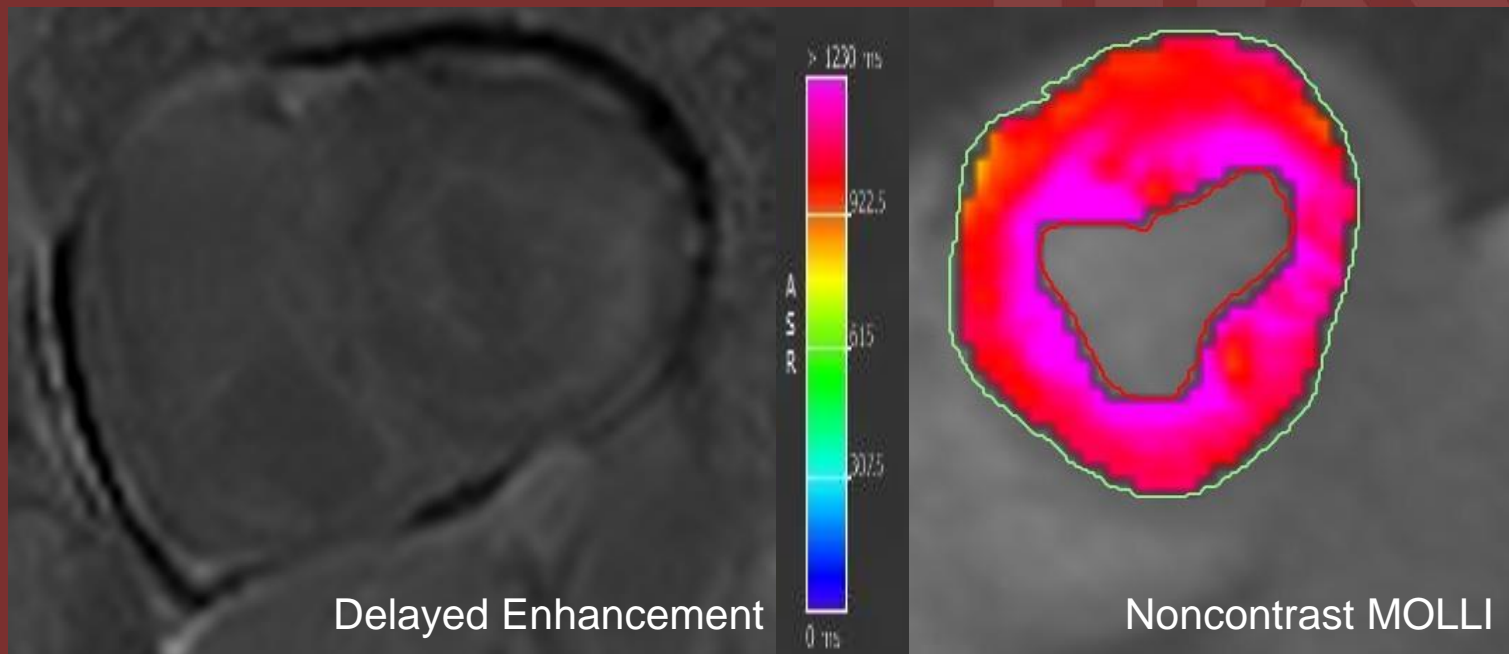


65 years old male with known diagnosis of multiple myeloma and restrictive cardiac physiology



Delayed enhancement shows diffuse right and left ventricular enhancement, predominantly subendocardial. Color map of Native (non-contrast) T1 mapping showing diffuse subendocardial increased Native T1 value with measurement up to 1350 msec (measurements not shown).

Diagnosis: Cardiac Amyloidosis

- Delayed enhancement images are difficult to interpret in Cardiac Amyloidosis due to the diffuse infiltrative process (hard to choose an optimal T1 time to null the normal myocardium)
- T1 time without contrast (Native T1) helps identifying diffuse process
- Gadolinium is a relative contraindication for patients with renal failure

Dhiraj Baruah, MD, FSCMR, FNASCI
Medical University of South Carolina