

NORTH AMERICAN SOCIETY FOR  
CARDIOVASCULAR IMAGING

48 year old gentleman with known metastatic bowel malignancy, recent onset worsening dyspnoea and fatigue.

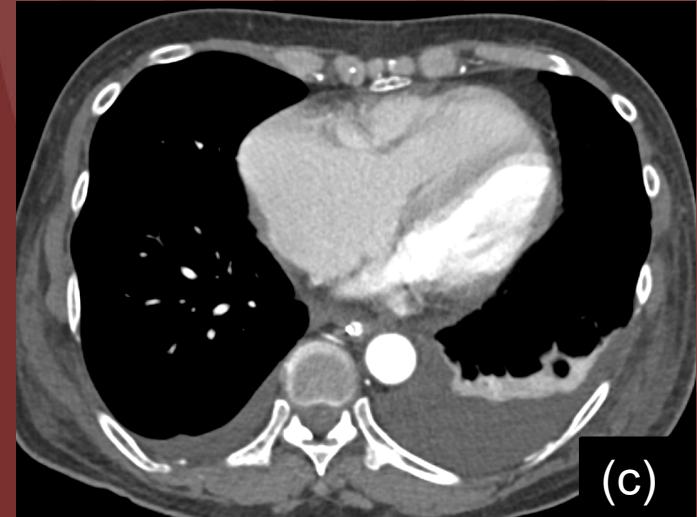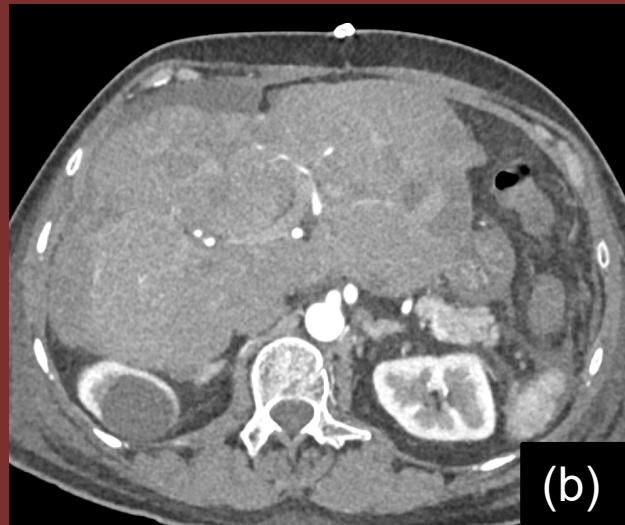
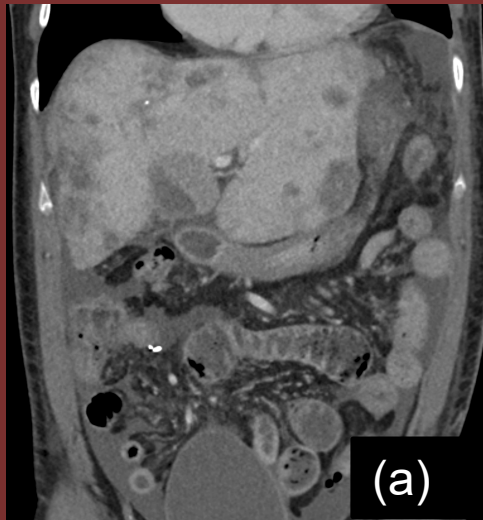


Figure legend: (a) post contrast venous phase abdomen, arterial phase axial upper abdomen, (b) and lower chest (c)

# DIAGNOSIS:

Carcinoid heart disease secondary to metastatic neuroendocrine tumor (NET) of the small bowel.

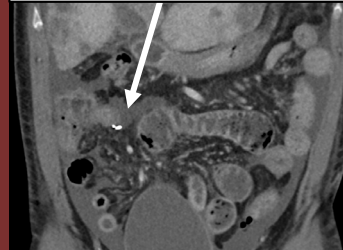
## TEACHING POINTS

### *Imaging clues of carcinoid heart disease:*

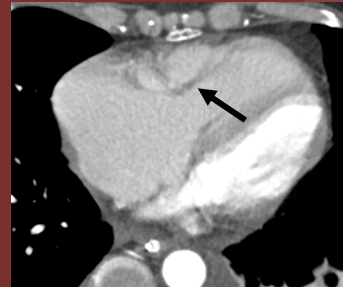
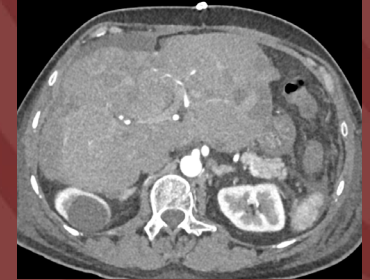- a. *Thickened valve leaflets with dilated heart chambers due to regurgitant valve. (RV > LV on non gated CT chest)*
- b. *Restricted mobility of affected valve leaflets on retrospective CT or cine MRI.*

1. In the right clinical scenario, these findings must alert the radiologist to the possibility of cardiac involvement being the cause of clinical deterioration
2. Carcinoid heart disease:
  - Typically tricuspid valve regurgitation (100%).
  - Pulmonary regurgitation (81%).

*Surgical Staples Of Resected NET Small Bowel*



*Diffuse hepatic metastasis*



*Finding a*



*Finding b*

Author: Romina D'Souza  
Institution : Sickkids, Toronto