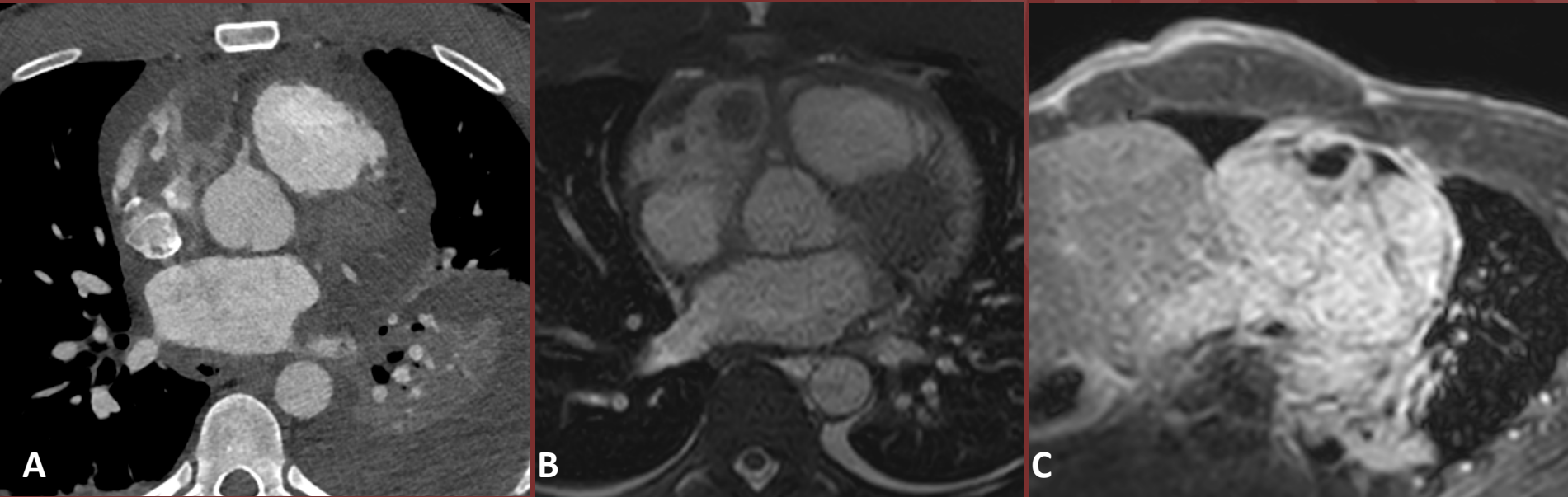


NORTH AMERICAN SOCIETY FOR
CARDIOVASCULAR IMAGING

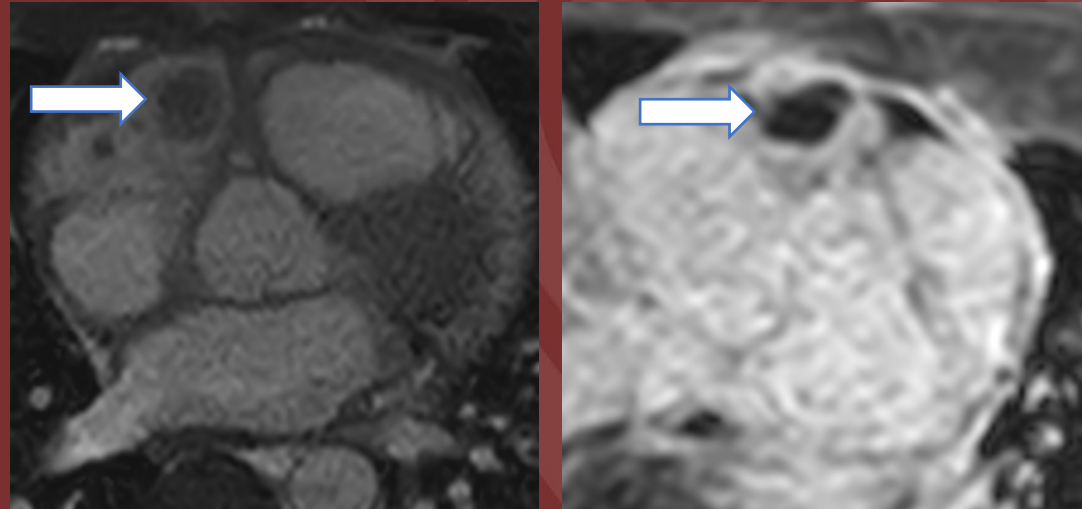
Young male presenting with pericarditis and pericardial
tamponade.



(A) contrast enhanced CT, (B) T2 weighted MRI, and (C) post contrast MRI

Diagnosis: Pathology confirmed angiosarcoma

Cardiac angiosarcoma is a rare endothelial cell tumor which can present with severe manifestations such as myocardial rupture and cardiac tamponade. Most commonly found in the right atrium, this tumor usually demonstrates heterogenous enhancement on post-gadolinium imaging. Despite this case's atypical imaging features, biopsy was performed given family history of cardiac angiosarcoma.



Mass within the right atrial appendage on T2 weighted imaging (left) which shows atypical non-enhancement on post-contrast T1 weighted imaging (right).

Shamus Moran, MD

University of Washington