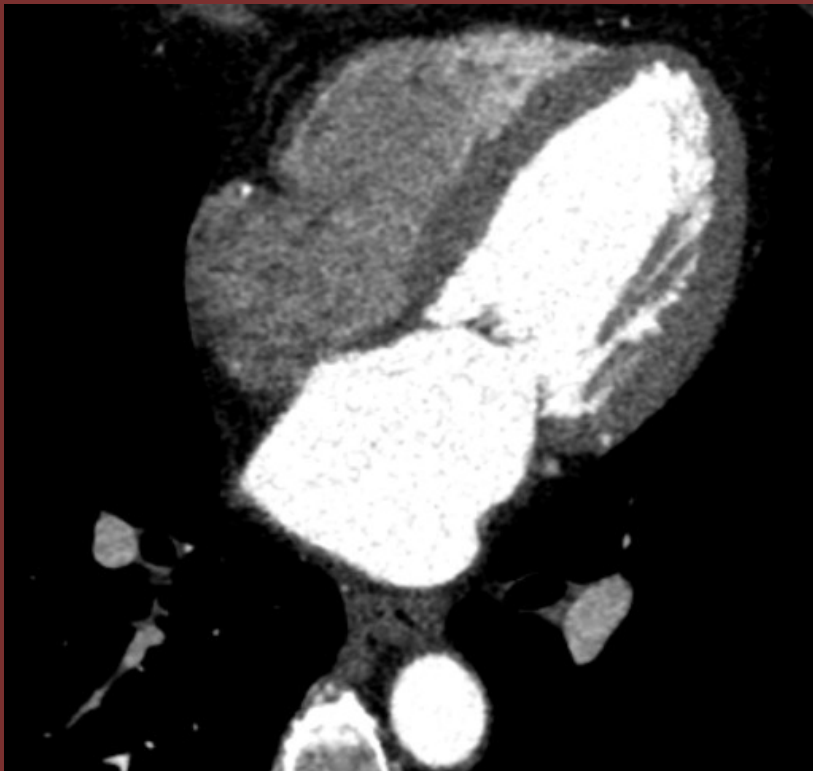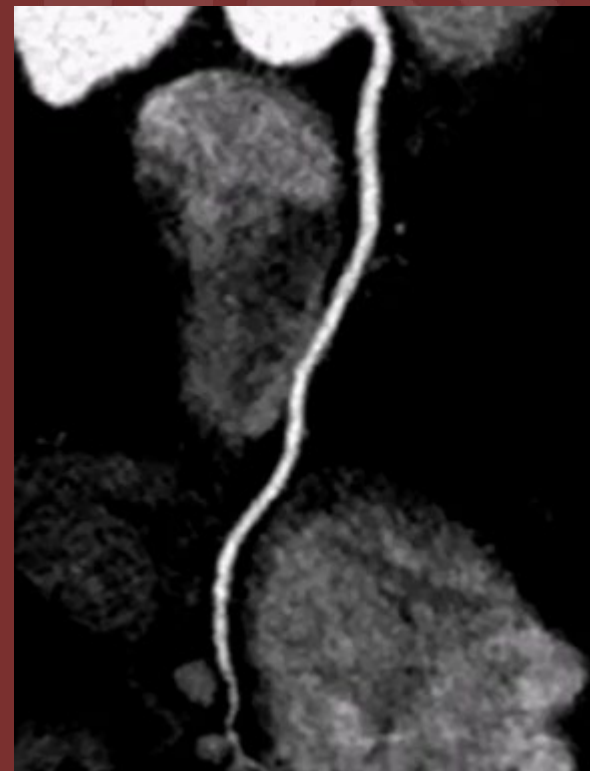


**57 year-old female with several months of
exertional angina**



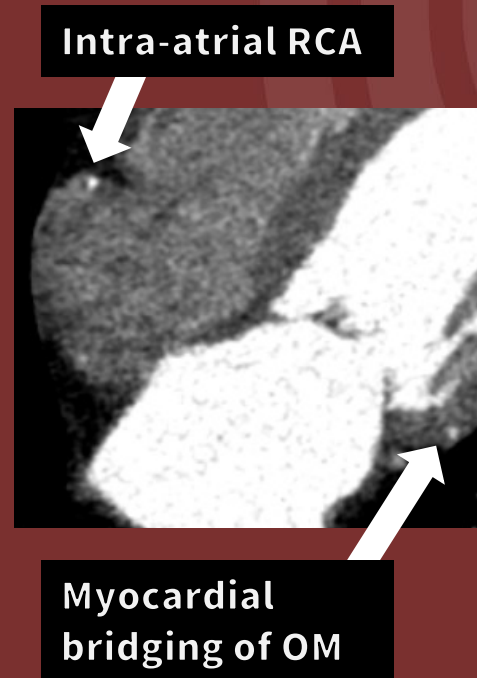Axial four chamber reformat



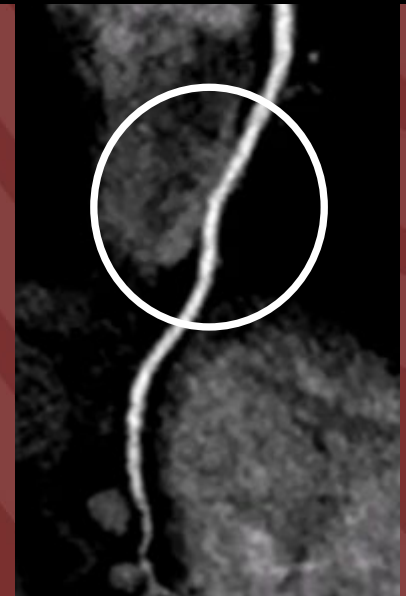
RCA – curved reformat cine

Diagnosis: Intra-atrial course of RCA

Intra-atrial course of the RCA is a rare anomaly with the RCA courses into and out of the right atrial chamber at variable depth, which may put the RCA at risk during cardiac intervention with right atrial cannulation. Additional finding of myocardial bridging of the obtuse marginal artery (OM) as shown.



RCA located circumferentially within right atrial myocardium



Brian Fagel, MD; Luba Frank, MD - Vanderbilt University Medical Center