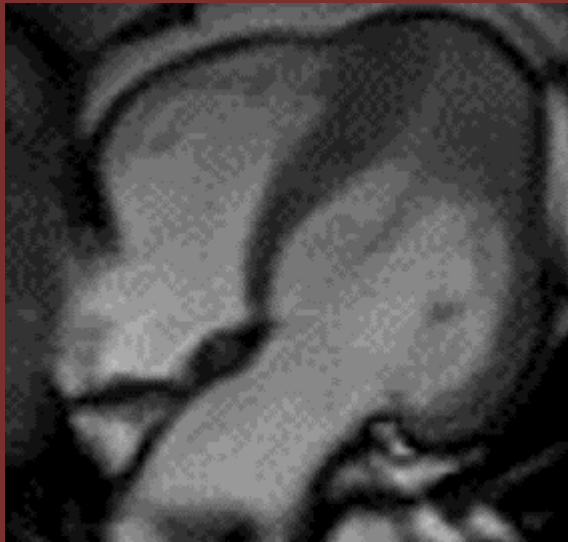

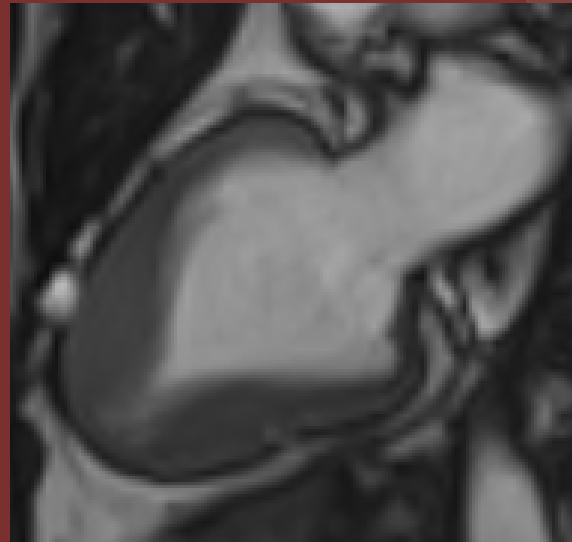NORTH AMERICAN SOCIETY FOR
CARDIOVASCULAR IMAGING

72-year-old female with hypertension and
suspected HCM



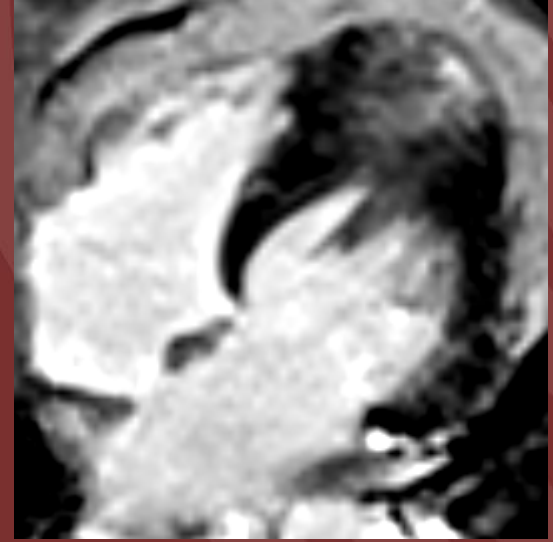
A

(A) Cine 4CB



B

Cardiac MR
(B) Cine VLA



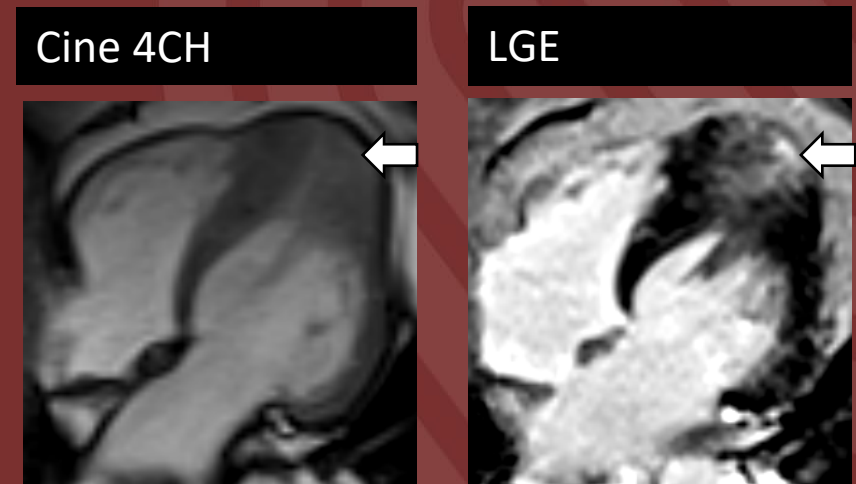
C

(C) LGE 4CH

Diagnosis: Apical hypertrophic cardiomyopathy

Apical hypertrophic cardiomyopathy (**Yamaguchi syndrome**), is a variant of cardiomyopathy that affects the apical region of the left ventricle.

Ace-of-spades sign refers to the pathognomonic configuration of the left ventricle. Cardiac MRI may show associated local delayed enhancement on LGE images.



Shaoxiong Zhang, MD

Cleveland Clinic

Reference(s): Apical Hypertrophic Cardiomyopathy: The Ace-of-Spades as the Disease Card

Camelia C. Diaconu, Nicoleta Dumitru, Ana G. Fruntelata, Smarandita Lacau, Daniela Bartos
Acta Cardiol Sin. 2015; 31(1): 83–86.