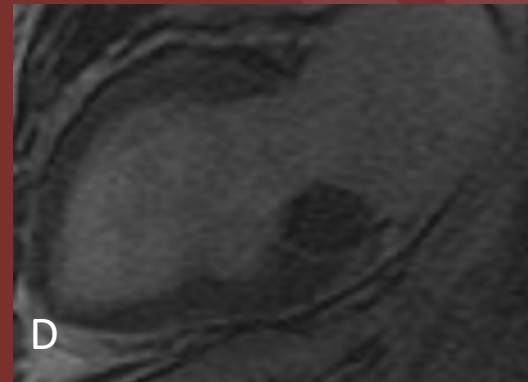
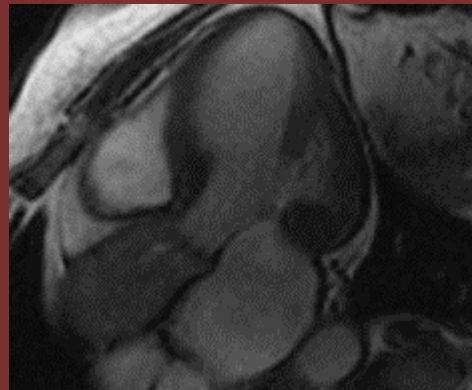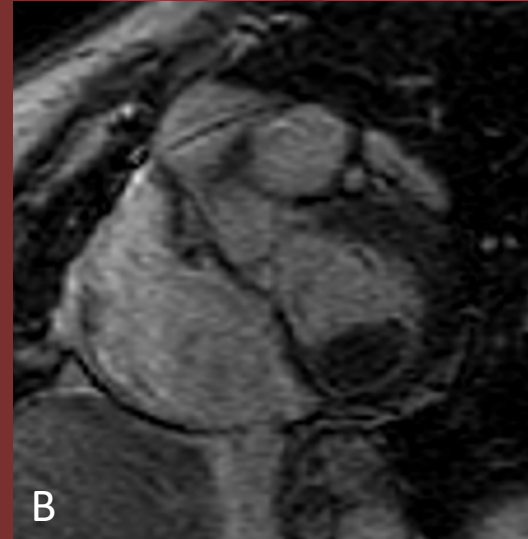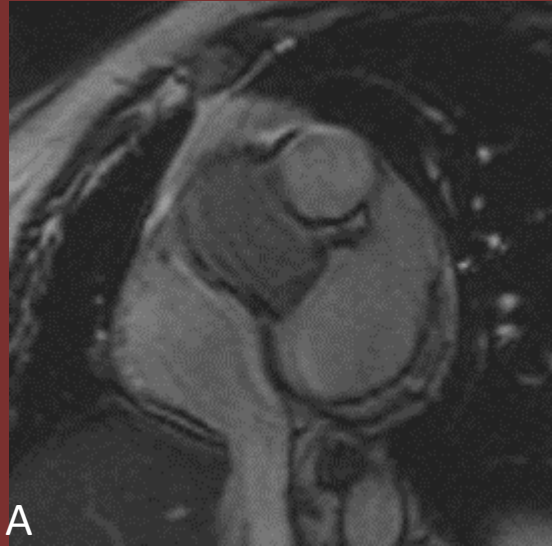


75 year old female with dyspnea and mass on TTE



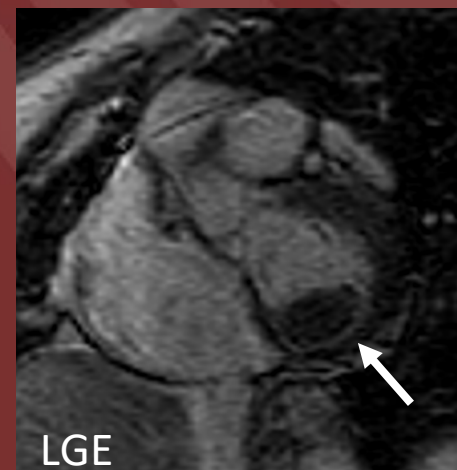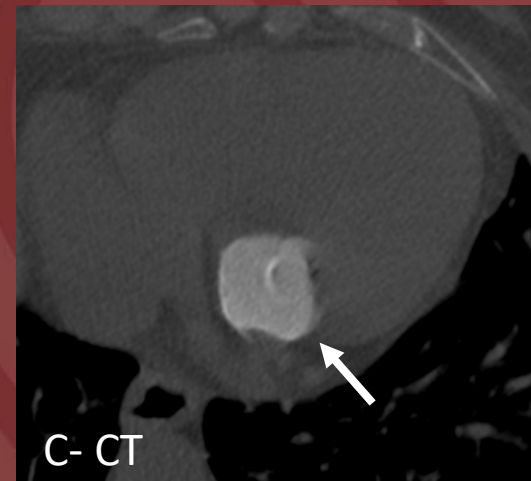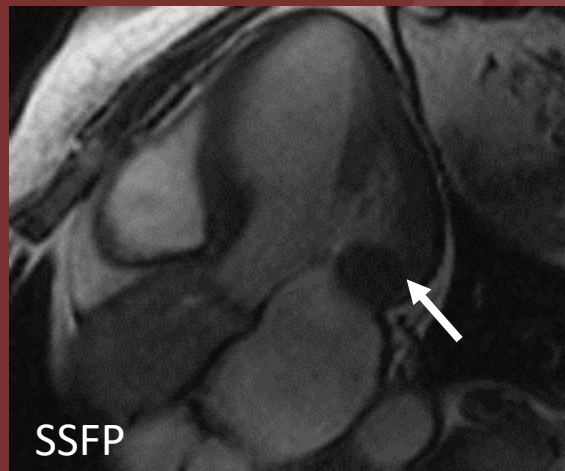
(A, C) SSFP

(B,D) Late Gadolinium Enhancement

Diagnosis: Mitral annular calcification

Mitral Annular calcification is a common “mass” identified on echo. Diagnosis on non contrast CT is straightforward but MR imaging patterns are less well known.

The mass is attached to the ventricular side of posterior mitral leaflet. It is isointense to myocardium on SSFP sequences (arrow) and hypointense on T1 and T2. On delayed phase there is no central enhancement but there is peripheral enhancement due to associated fibrous cap (arrow).



Shira Steinberger, MD; Joanna Escalon MD; Jessica Patel MD;
Alan Legasto MD

Weill Cornell Medicine