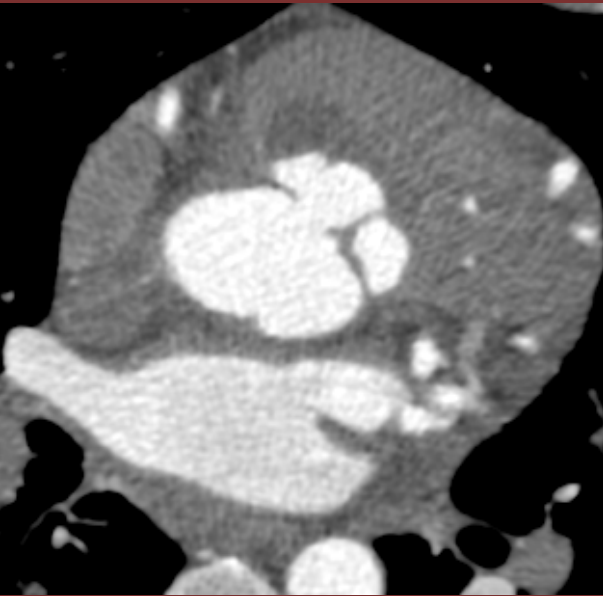
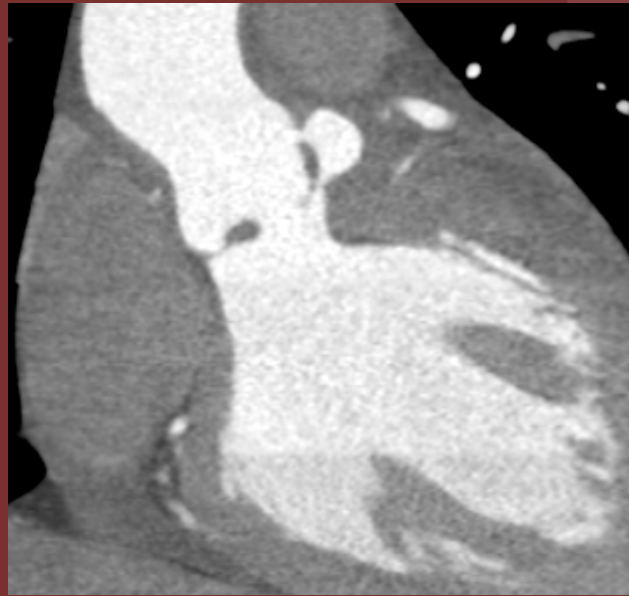


28-year-old male with fever



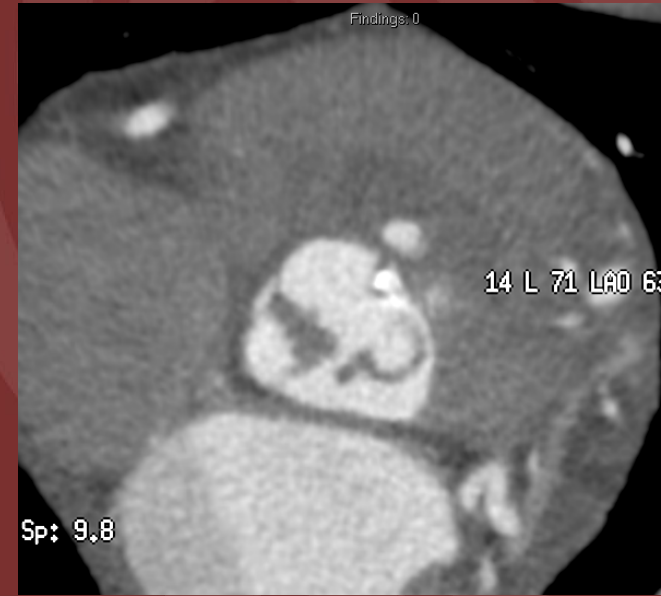A

(A) Axial



B

CTA of the Coronary Arteries
(B) Coronal

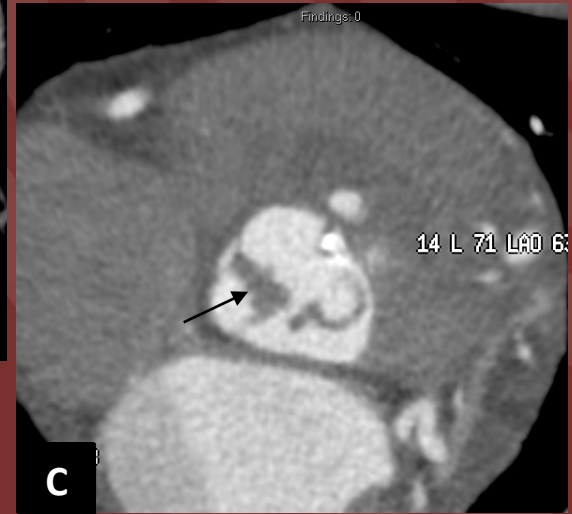
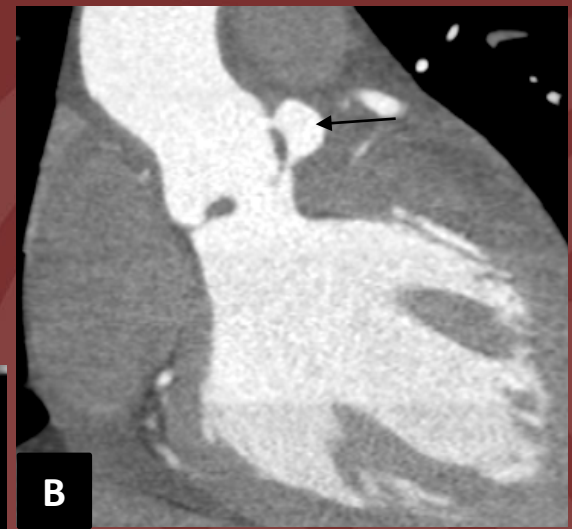
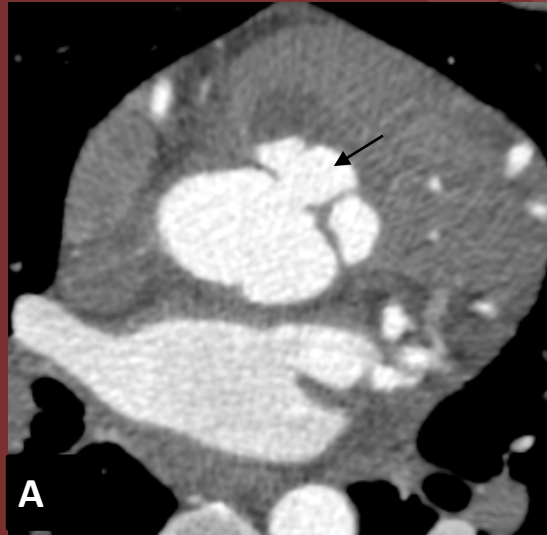


C

(C) Axial

Diagnosis: Perivalvular Abscess

Perivalvular abscess is a feared complication of infective endocarditis with an incidence of 29% in native valves. The perivalvular abscess is seen as a contrast-filled cavity adjacent to the aortic valve on Images A and B. Image C demonstrates nodular hypoattenuation and thickening of the non-coronary cusp, reflective of vegetation.



Louis Mercado, MD and Nikhil Goyal, MD

Northwell Health System

Reference(s):

Role of Cardiac CT in Infective Endocarditis: Current Evidence, Opportunities, and Challenges

Mnahi Bin Saeedan, Tom Kai Ming Wang, Paul Cremer, Ali R. Wahadat, Ricardo P. J. Budde, Shinya Unai, Gosta B. Pettersson, and Michael A. Bolen

Radiology: Cardiothoracic Imaging 2021 3:1