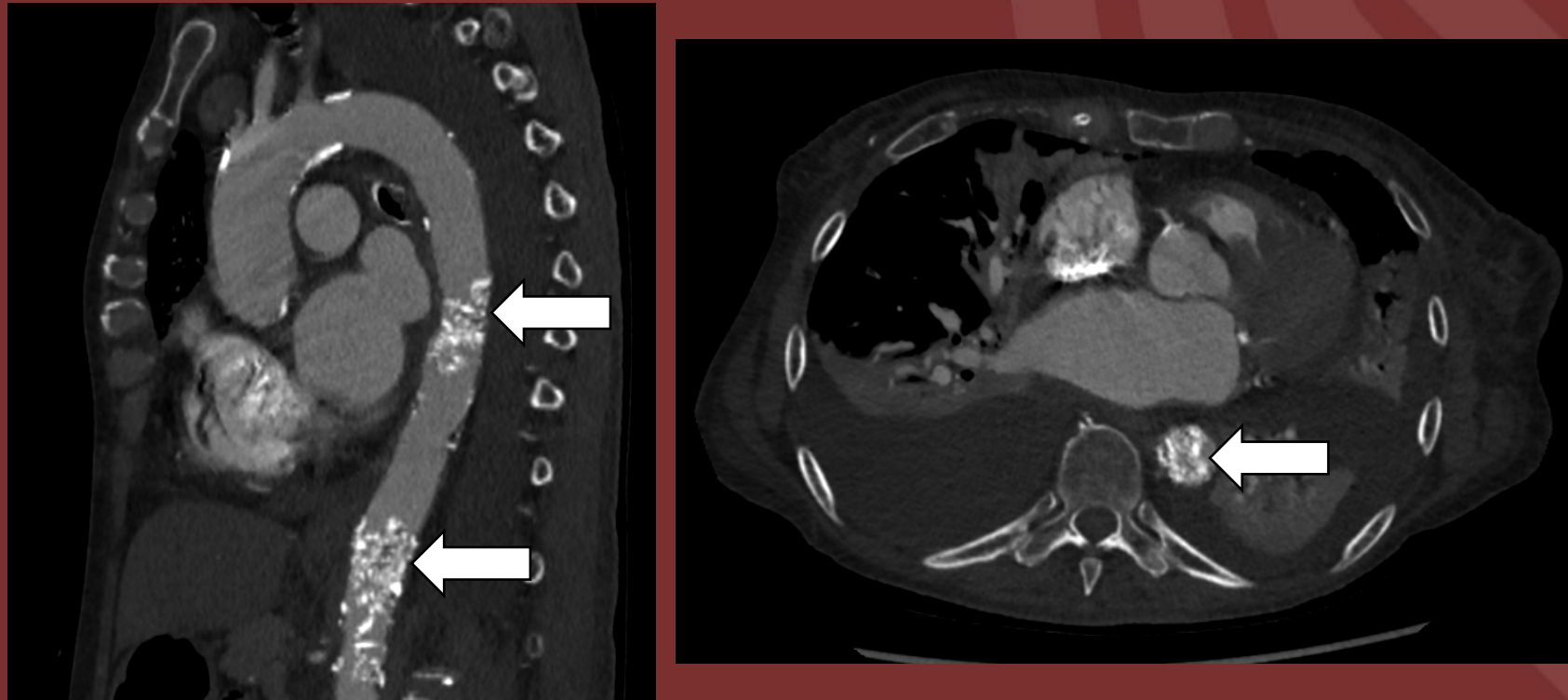


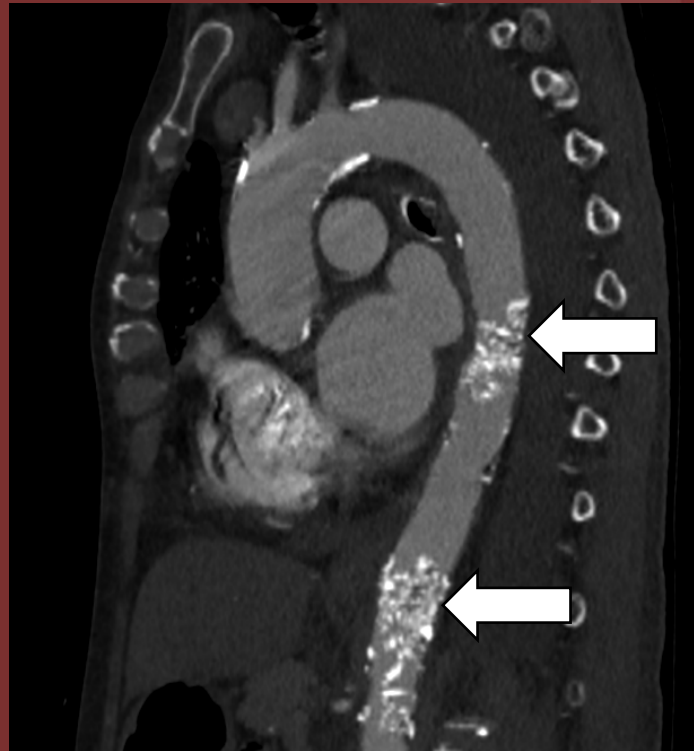
The 50th Anniversary
Fantastic Cases In Cardiovascular Imaging. Case 49

History: 69-year-old heavy smoker with claudication symptoms.



Figure(s): CTA chest demonstrates two sites of severe aortic calcifications protruding into and partially obstructing the thoracic aortic lumen .

Diagnosis: Coral reef aorta.



Matthew Cham, MD. University of Washington