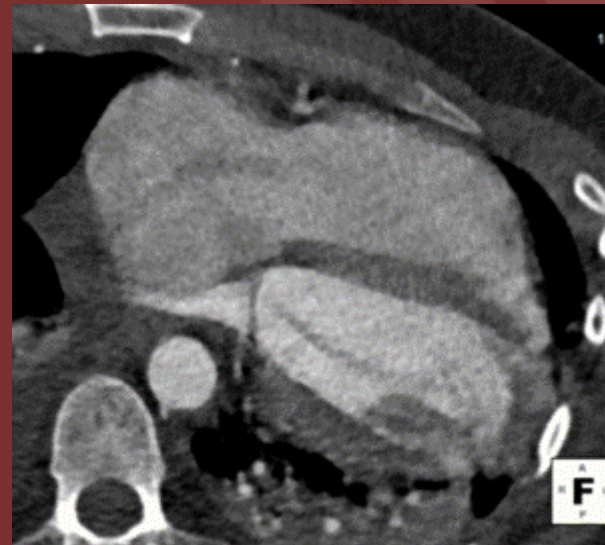
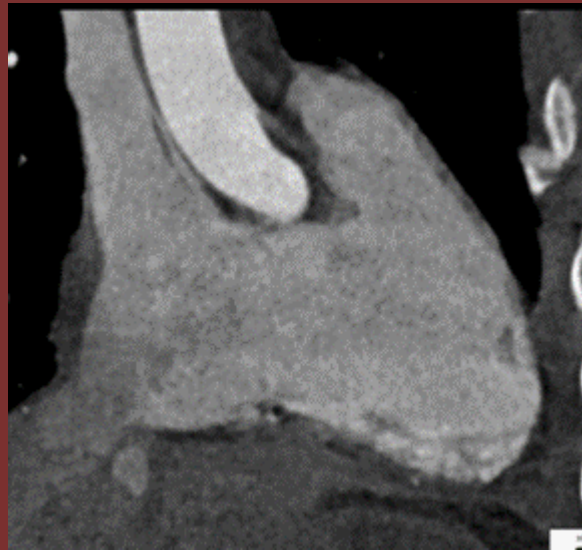

NORTH AMERICAN SOCIETY FOR
CARDIOVASCULAR IMAGING

The 50th Anniversary
Fantastic Cases In Cardiovascular Imaging. Case 46

History: Fall from 30 ft



Retrospectively gated cardiac CT shows prolapsing tricuspid valve leaflets. Notice displacement into the right atrium during systole.

NORTH AMERICAN SOCIETY FOR
CARDIOVASCULAR IMAGING

Diagnosis: Traumatic Rupture of the Tricuspid chordae tendinae

Author: Daniel Vargas, MD FNASCI

University of Colorado Anschutz Medical Campus