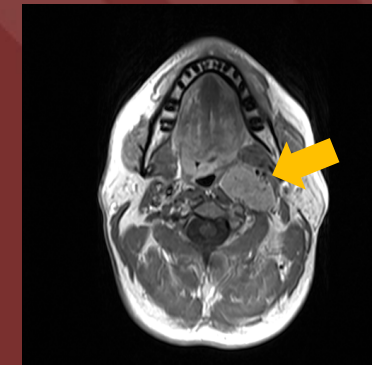
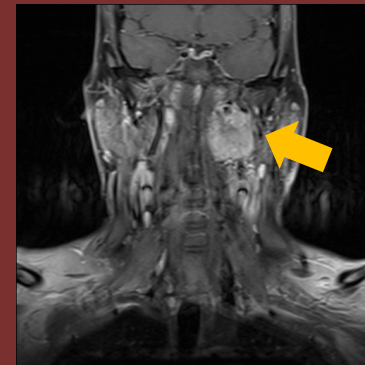
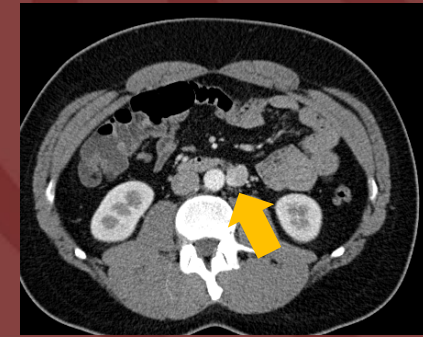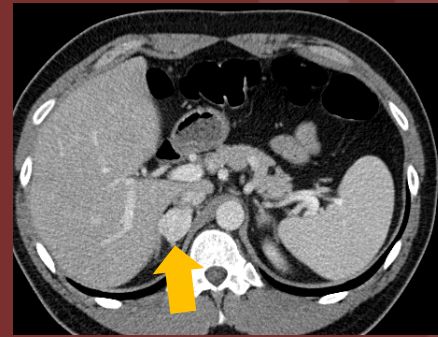
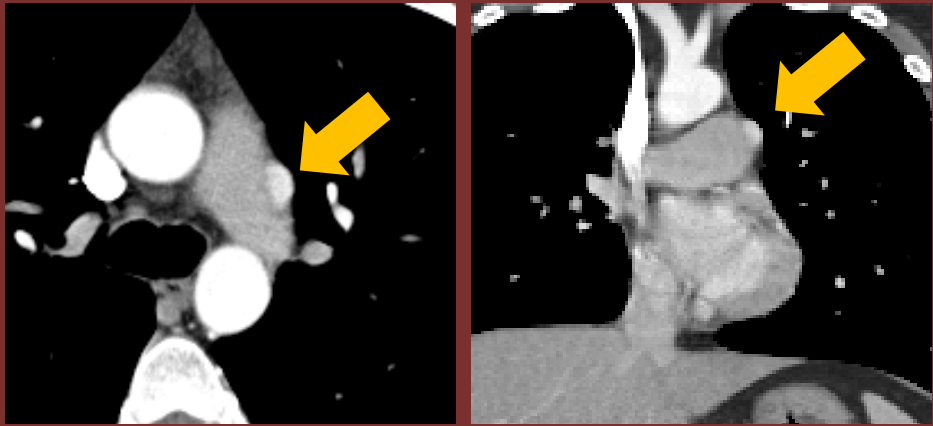


The 50th Anniversary
Fantastic Cases In Cardiovascular Imaging. Case 45

History: 32 year-old man



Cardiac CT (above) shows an intrapericardial avidly enhancing mass adjacent to the proximal left pulmonary artery. Abdominal CT (top right) showing enhancing masses in the right adrenal and left retroperitoneum. Neck MR (bottom right) showing masses at the left carotid bifurcation and jugular foramen.

Diagnosis: Intrapericardial Paraganglioma in a Patient with Hereditary Pheochromocytoma-Paraganglioma Syndrome

Also in the same patient: Right adrenal pheochromocytoma, left retroperitoneal paraganglioma, left glomus jugulare and bilateral carotid body paragangliomas.

Succinate Dehydrogenase gene mutations

Author: Daniel Vargas, MD FNASCI

University of Colorado Anschutz Medical Campus