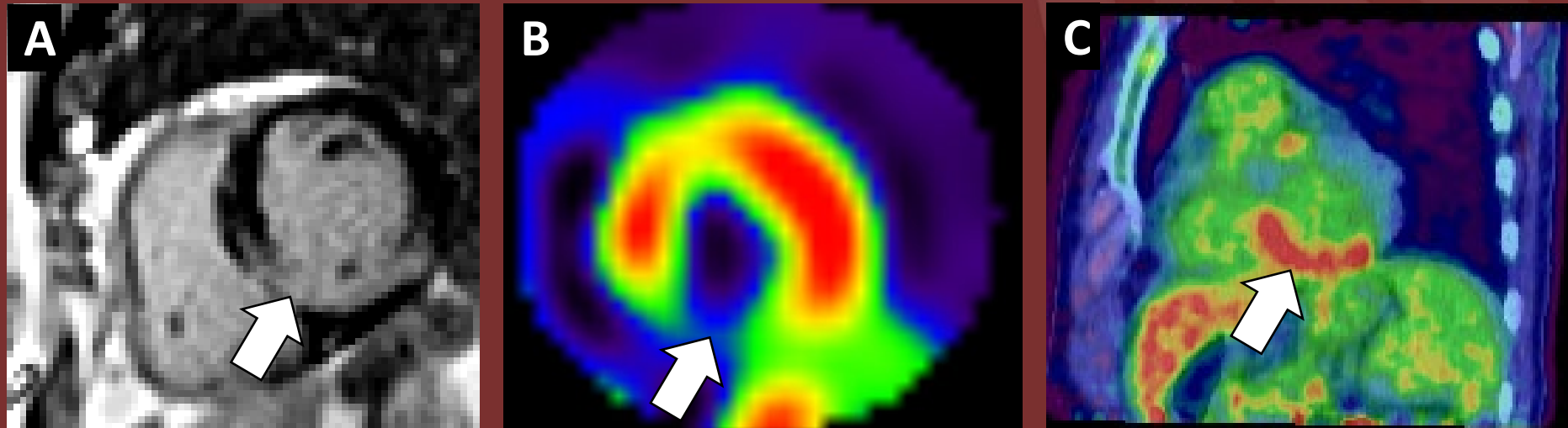


The 50th Anniversary

Fantastic Cases In Cardiovascular Imaging. Case 41

History: 64 year-old-male with a more than 6 month history of shortness of breath and reported cardiac conduction abnormality



**Figure(s):** (A) Cardiac MR PSIR short axis demonstrating transmural LGE at the mid-chamber inferoseptum and inferior wall. (B) Tc-99m-sestamibi myocardial perfusion study demonstrating decreased inferior wall perfusion at rest. (C) Cardiac 18F-FDG-PET/CT shows hypermetabolic activity at the inferior wall at site of decreased perfusion.

Diagnosis: Cardiac sarcoidosis

