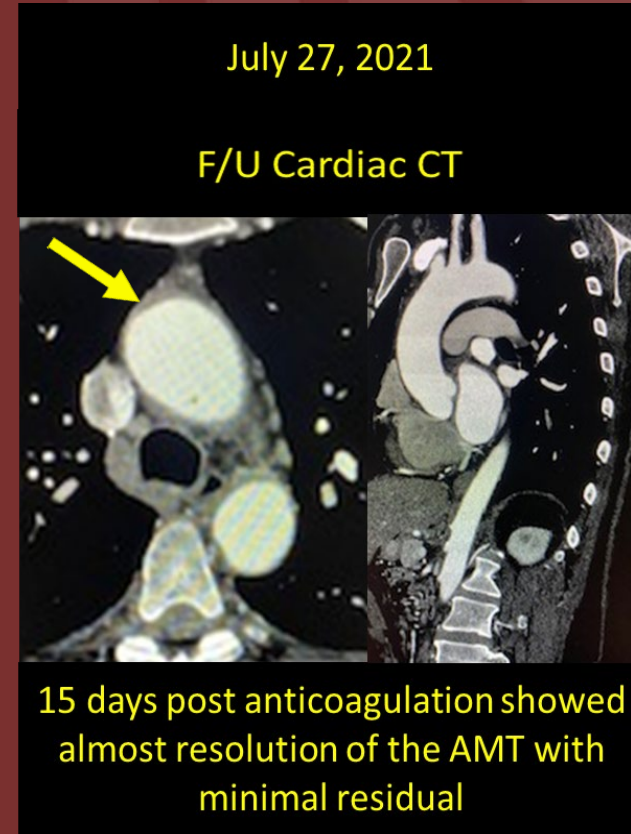
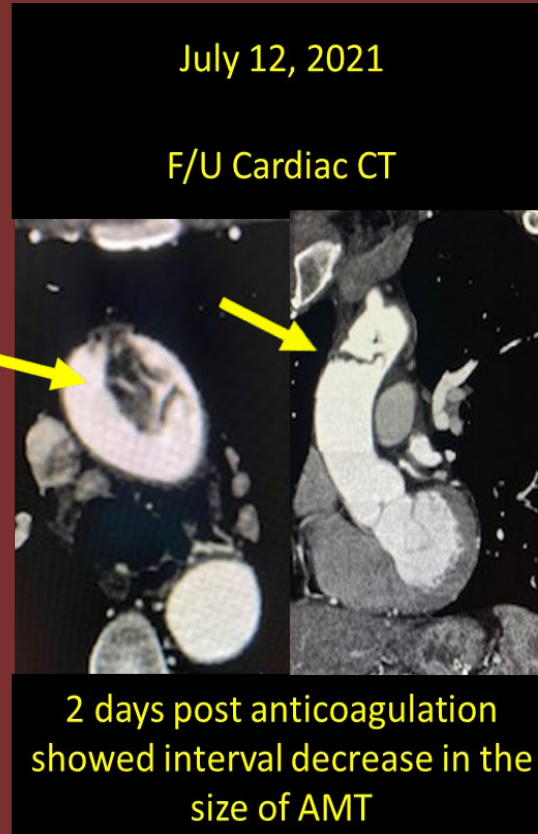
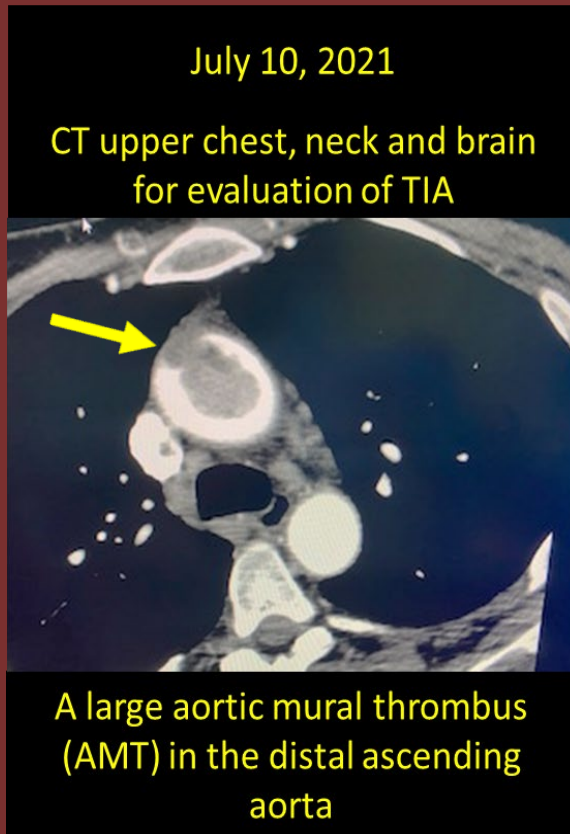


The 50th Anniversary

Fantastic Cases In Cardiovascular Imaging. Case 6

- **History:** 56-year-old male with COVID 19, presenting with TIA



Diagnosis: Aortic mural thrombus post-COVID19

Thrombus formation in the aorta is exceedingly rare. However, isolated cases have been attributed to COVID19.