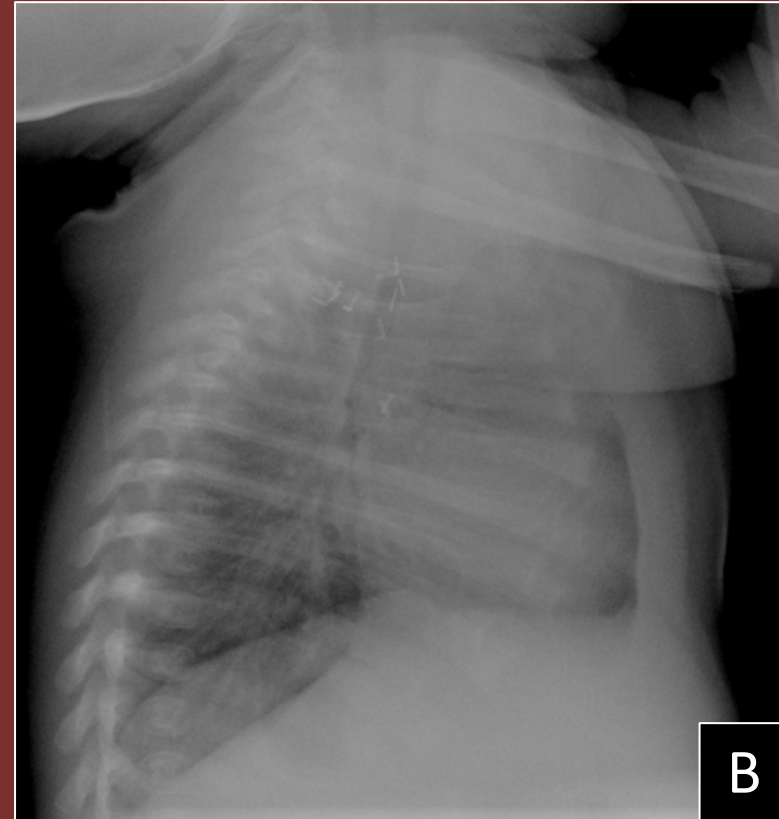
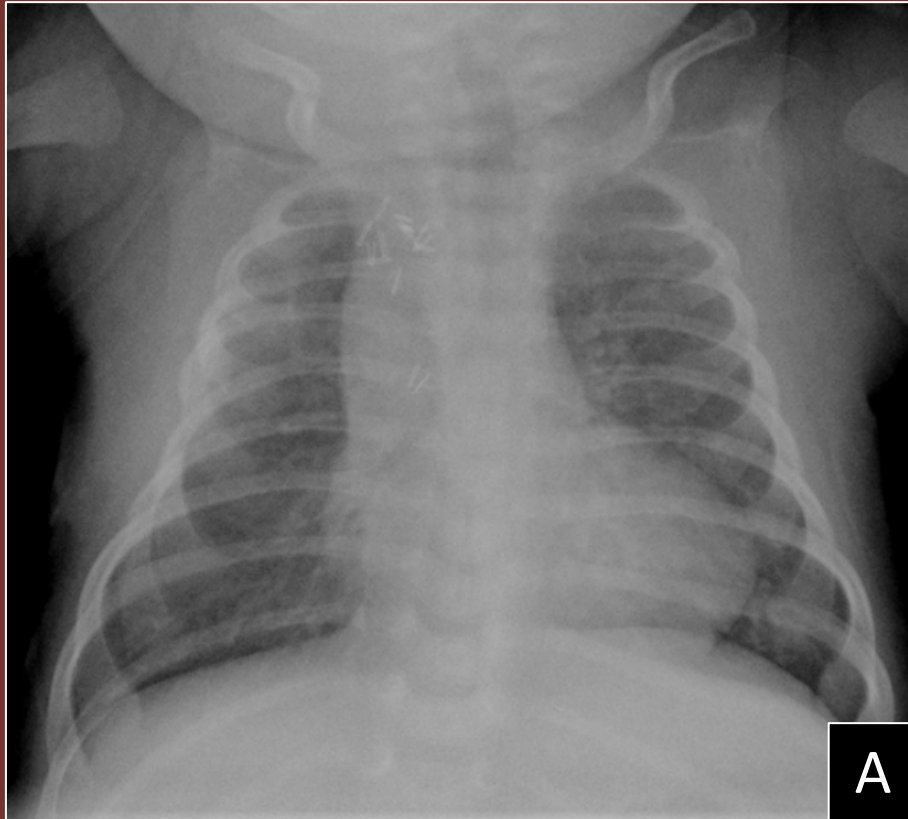


The 50th Anniversary

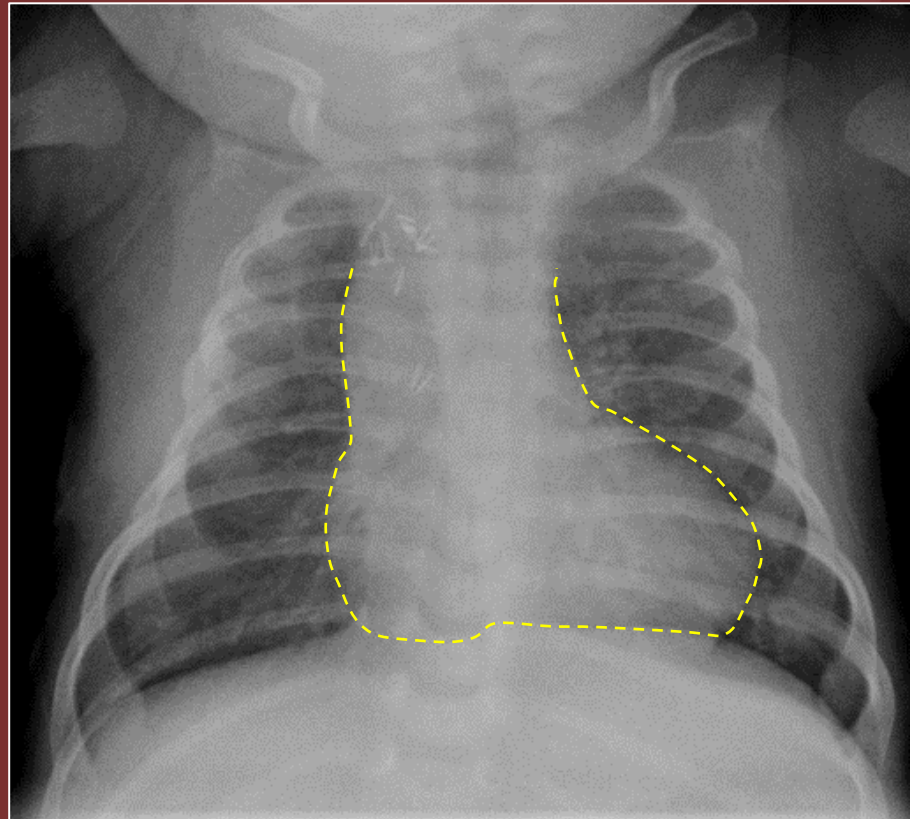
Fantastic Cases In Cardiovascular Imaging. Case 5

History: 1 month old female, with reduced oxygen saturation



A: PA, and B: Lateral, Chest Radiograph

Diagnosis: Cœur en sabot “boot-shaped heart”:
Tetralogy of Fallot (TOF).



Asmaa Ahmed, MD, Muhammad U. Aziz, MD, Padma Manapragada, MD, Mostafa Abozeed, MD, Satinder Singh, MD, University of Alabama at Birmingham