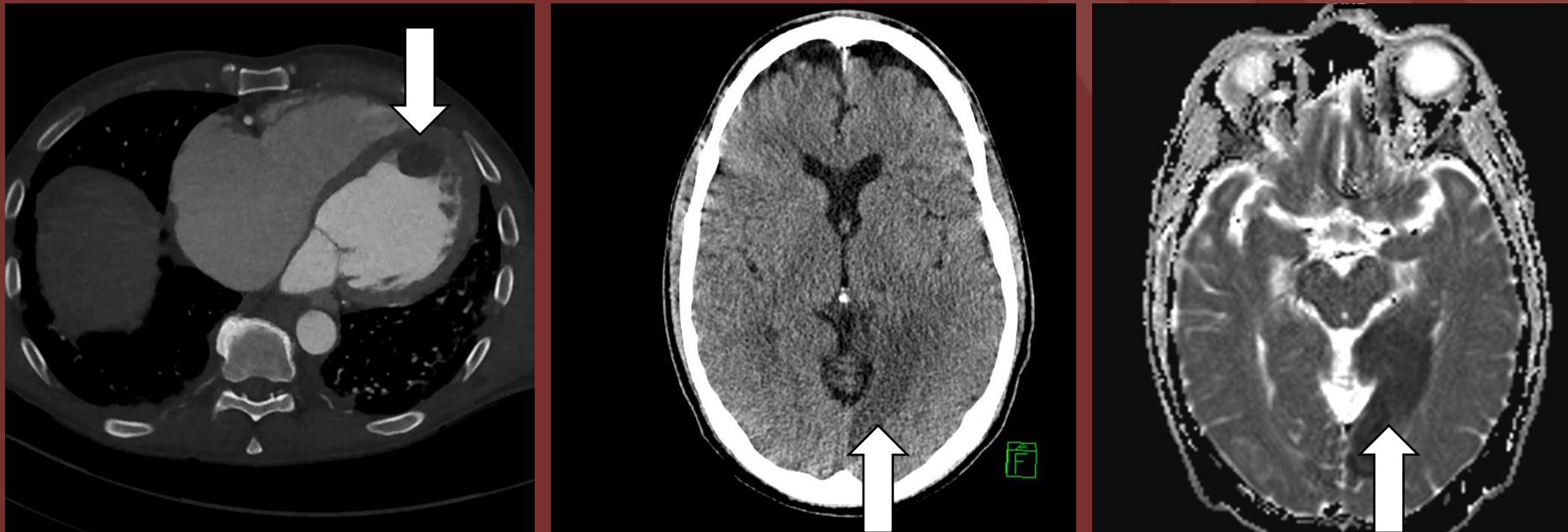


The 50th Anniversary
Fantastic Cases In Cardiovascular Imaging. Case 40

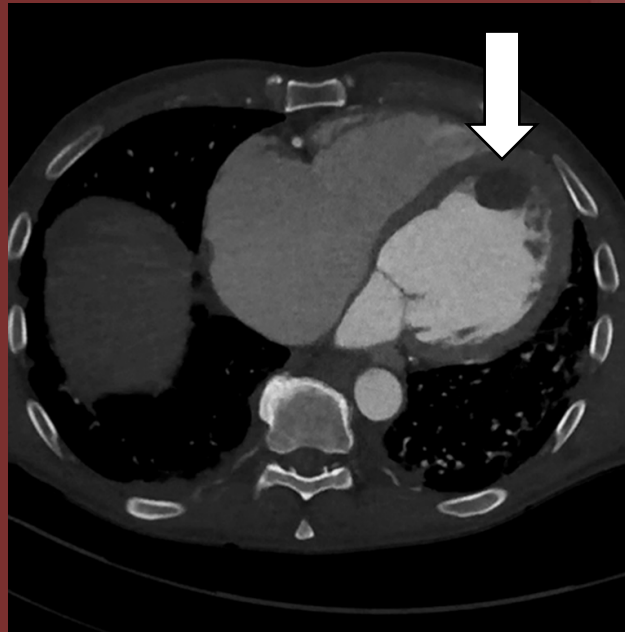
History: 62-year-old male who initially tested negative on PCR, and was sent home returns with NSTEMI and hemiparesis, and repeat COVID testing was positive.



Figure(s): CTA chest with left ventricular thrombus. Head CT with left occipital cortical hypoattenuation matched to restricted diffusion on brain MRI ADC map.

NORTH AMERICAN SOCIETY FOR CARDIOVASCULAR IMAGING

Diagnosis: COVID related intracardiac thrombus with resultant stroke.



Matthew Cham, MD. University of Washington