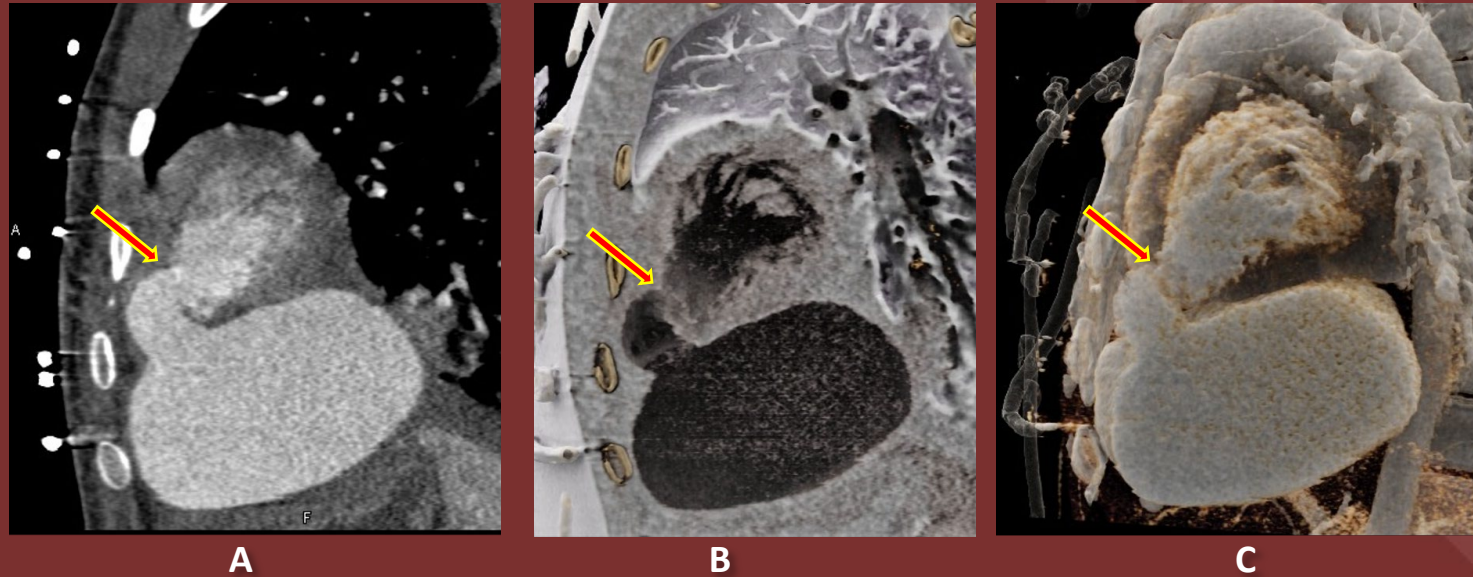


The 50th Anniversary
Fantastic Cases In Cardiovascular Imaging. Case 4

History: 16-year-old male with history of a gunshot wound to the heart.



Figure(s): Sagittal chest CT (A) shows narrow aneurysmal neck at anterior left ventricle with large pseudoaneurysm. Cinematic Rendering images depict the detailed contour of the pseudoaneurysm (B, C)

Diagnosis: Massive left ventricular pseudoaneurysm from gunshot wound.

LV pseudoaneurysms can be identified by a narrow-necked communication with the LV cavity and a wide base.

Abdullah Al Khalifah MD, Stefan Zimmerman MD, Elliot Fishman
MD Johns Hopkins Medicine – Department of Radiology