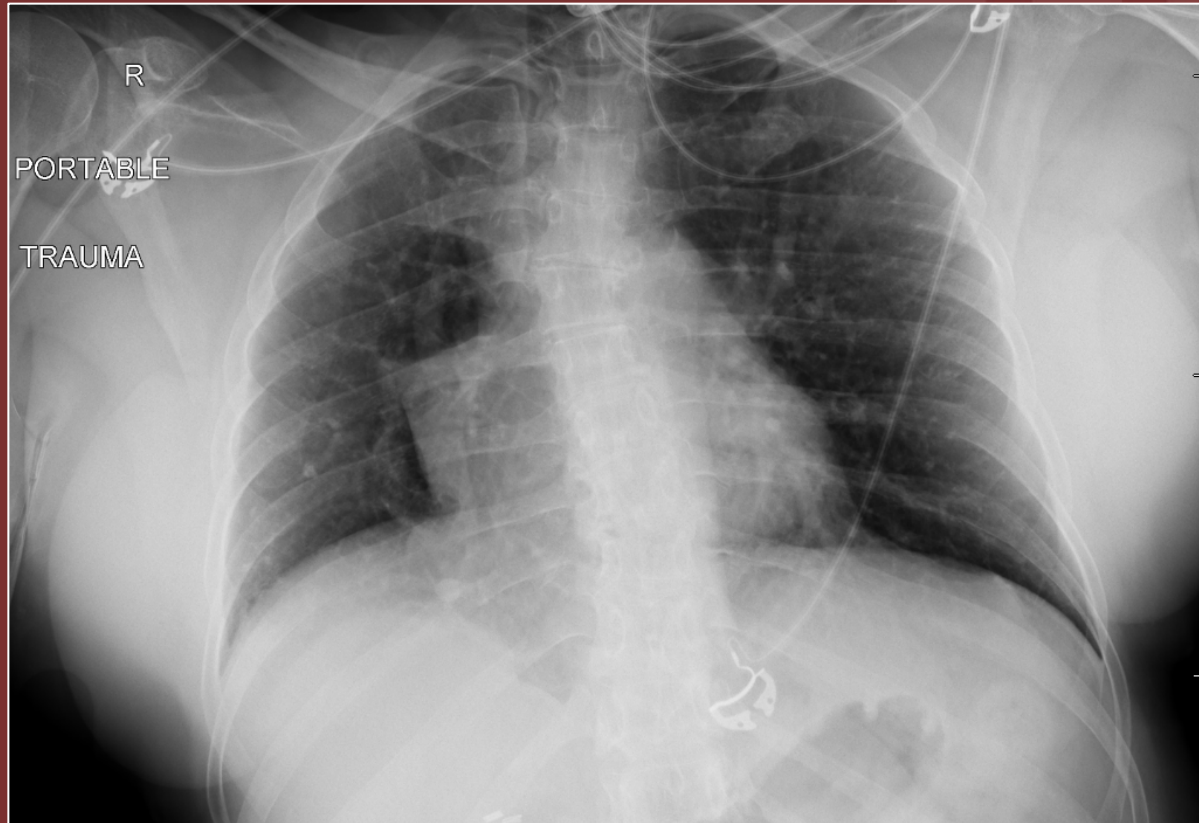


The 50th Anniversary

Fantastic Cases In Cardiovascular Imaging. Case 39

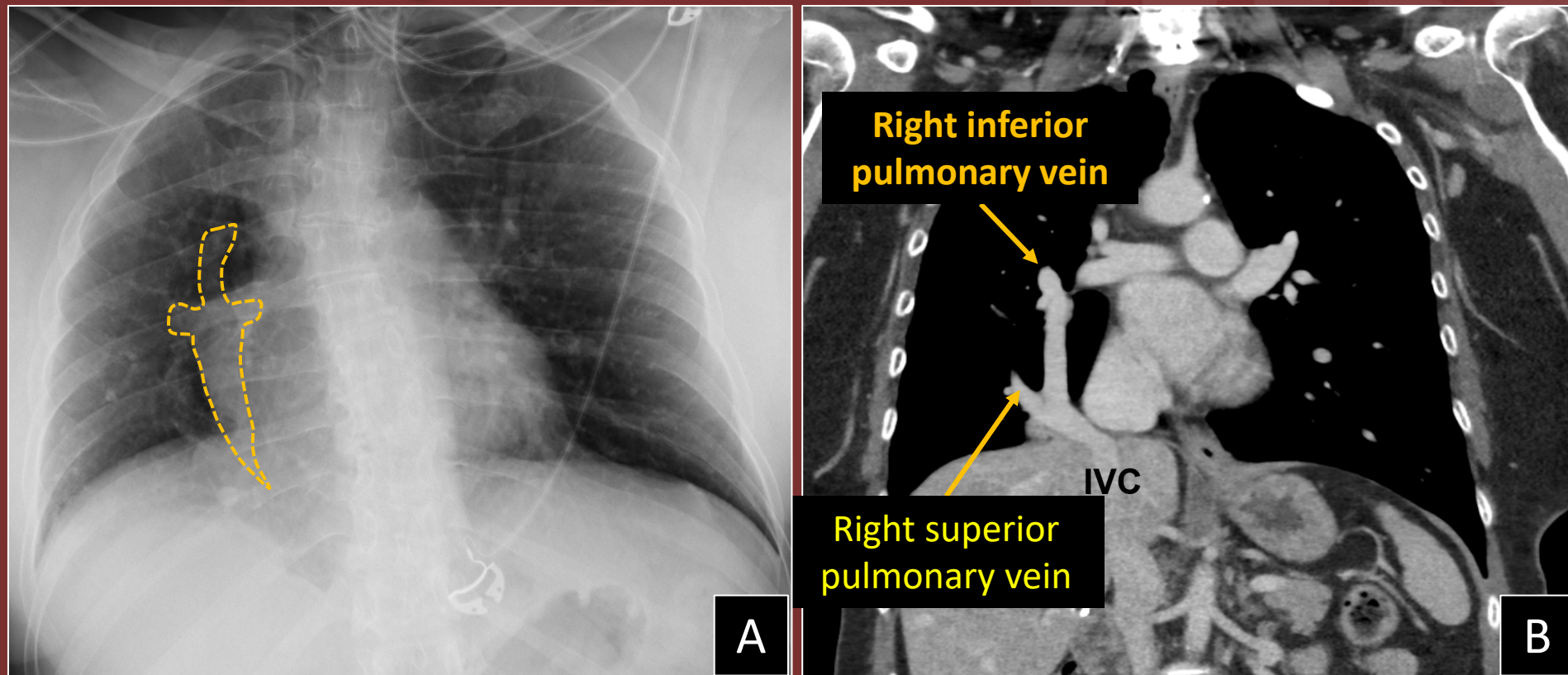
History: 53-year-old female, presenting with trauma



AP portable chest radiograph

Diagnosis:

Scimitar syndrome (A), with an anomalous pulmonary vein draining the right lung into the inferior vena cava (IVC) (B)



Asmaa Ahmed, MD, Muhammad U. Aziz, MD, Padma Manapragada, MD, Mostafa Abozeed, MD, Satinder Singh, MD, University of Alabama at Birmingham