

The 50th Anniversary
Fantastic Cases In Cardiovascular Imaging. Case 37

History: 33-year-old woman with atypical chest pain

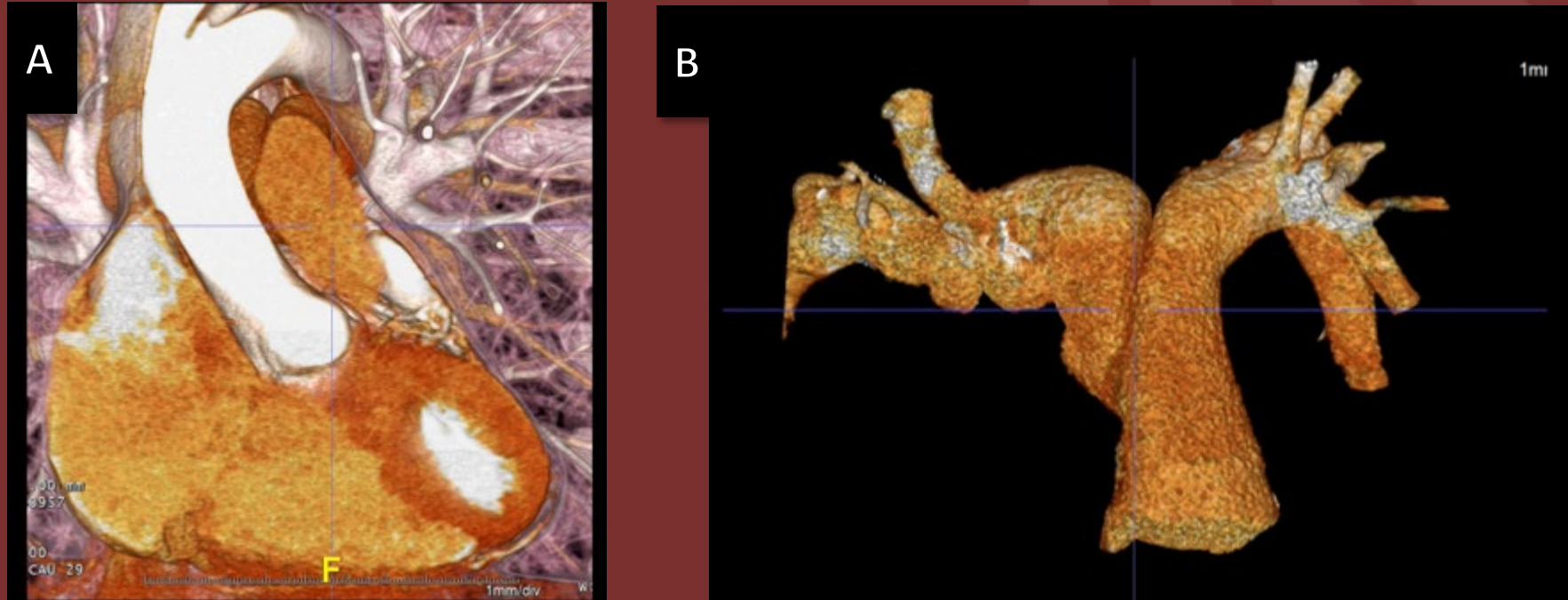


Figure: Cardiac CTA –Volume-renderings of the LVOT (A) and pulmonary arteries (B)

Diagnosis: Criss-cross pulmonary arteries

A rare malposition of the branch pulmonary arteries where the left pulmonary artery (PA) originates from the pulmonary trunk to the right and usually above the origin of the right PA and then they cross each other on their course to each respective lung. It is almost always associated with other congenital abnormalities but in this case, was not.