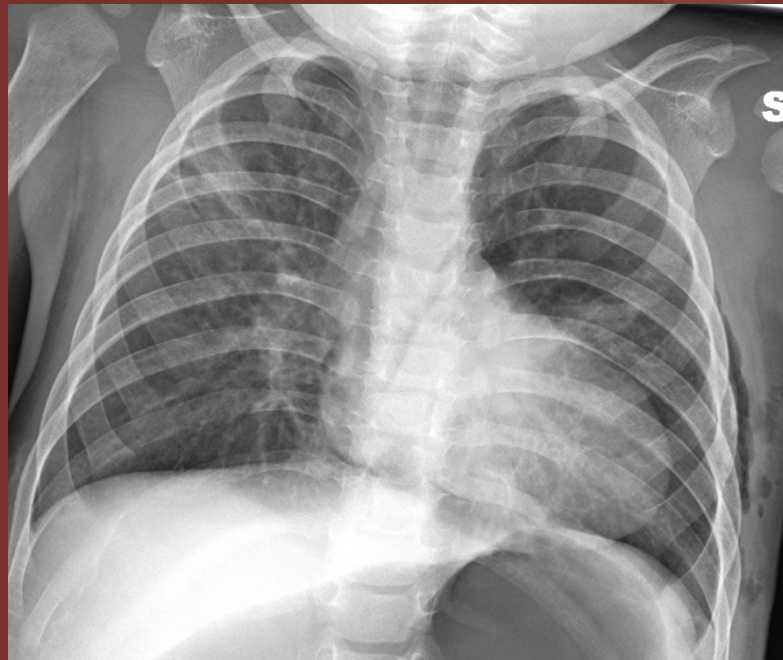


The 50th Anniversary

Fantastic Cases In Cardiovascular Imaging. Case 36

History: 8-month old boy post-pulmonary sequestration  
excision



**Figure:** Post-operative portable AP chest radiograph demonstrates abnormal elongation of the heart and flattening of the left heart border

Diagnosis: Absent pericardium (Snoopy sign)

