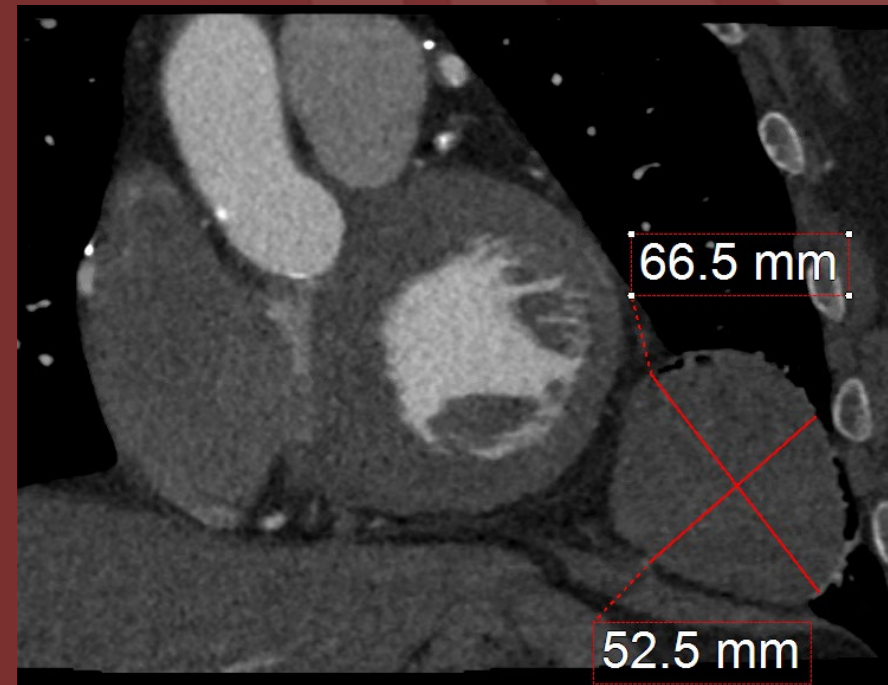
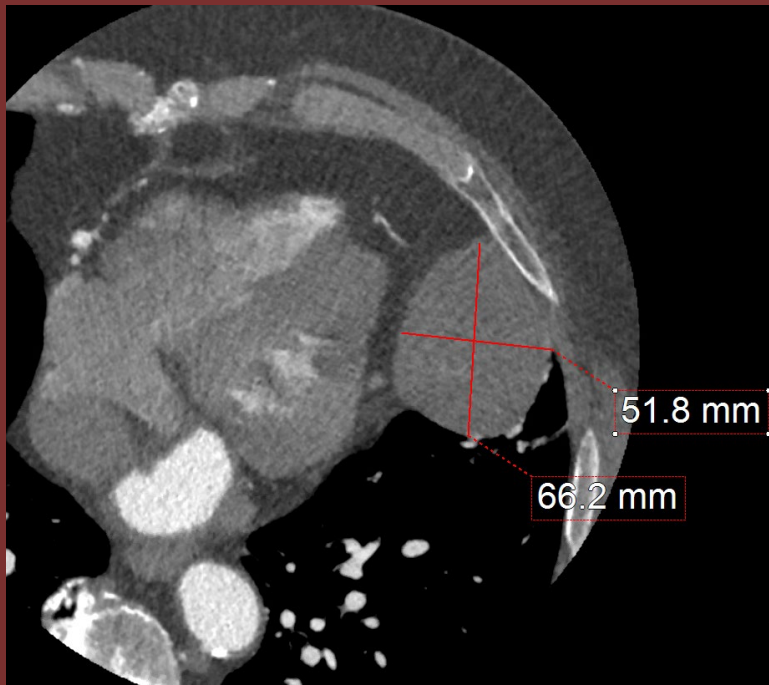

The 50th Anniversary

Fantastic Cases In Cardiovascular Imaging. Case 34

History: 81-year-old male with bypass surgery presented
with dyspnea on exertion



Short and long axis views showing a pericardial mass in the left inferior mediastinum.

Diagnosis by biopsy: Solitary fibrous tumor

Solitary fibrous tumor are rare benign growth of soft tissues that can occur anywhere in the body. Differentials in this case include pericardial cyst, loculated pericardial effusion, pleural metastases.

Author(s): Tung Nguyen, MD; Sethi Pooja, MD

Institution: Texas Tech University Health Science Center at Lubbock