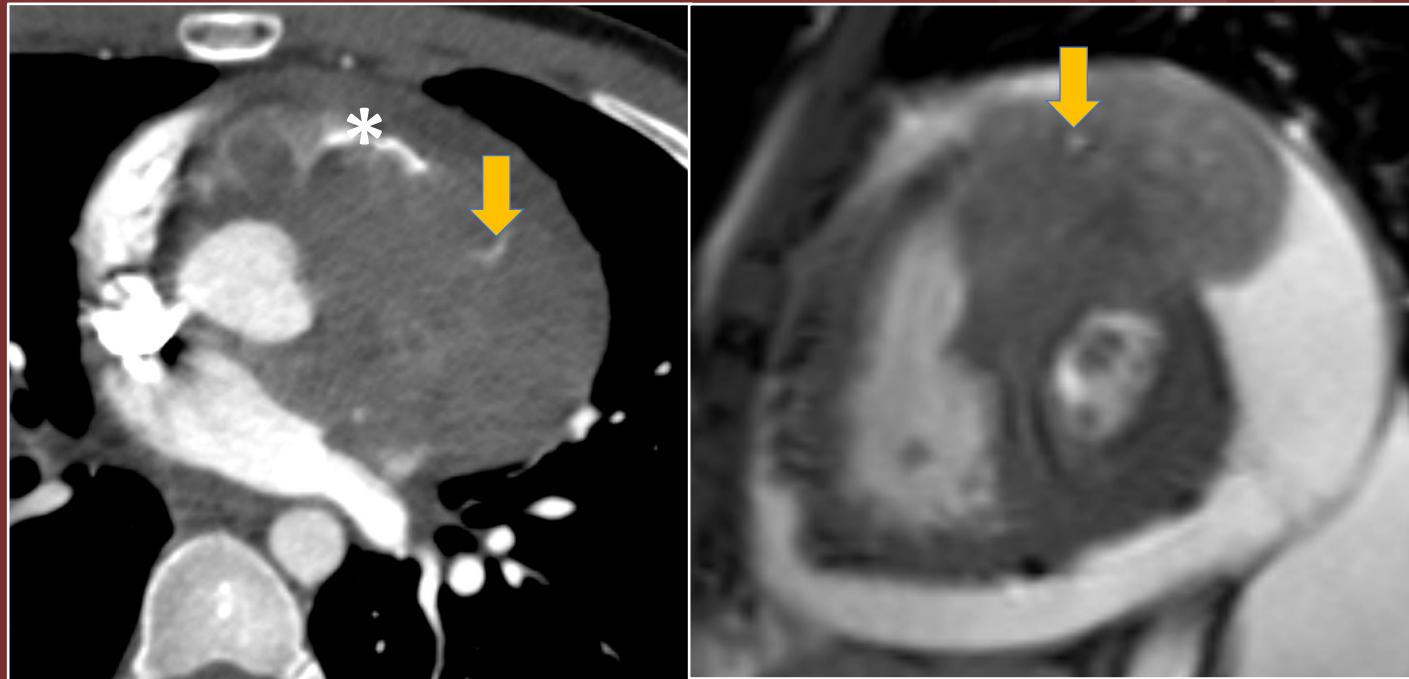


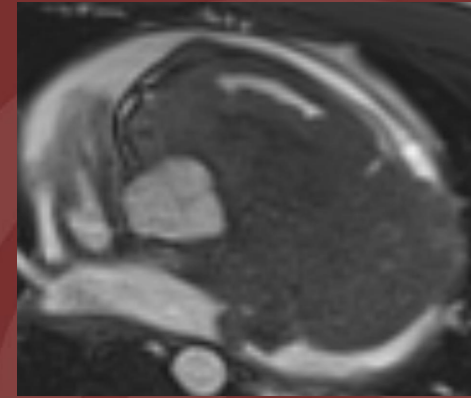
The 50th Anniversary

Fantastic Cases In Cardiovascular Imaging. Case 31

History: 20 year old man with shortness of breath.



**Figure(s):** CT and MRI demonstrating a lobulated, enhancing mass encasing the left main and LAD (arrow), invading the anterior septum and anterior wall of the left ventricle. The RVOT (\*) is narrowed by the mass.



**Diagnosis: Cardiac synovial sarcoma.**

Synovial Sarcoma involving the heart is very rare with poor prognosis. Cardiac synovial sarcoma comprise less than 5% of all primary sarcomas involving the pericardium or cardiac chambers.

**Elsie T. Nguyen MD, FRCPC, FNASCI**

**Associate Professor of Radiology, Peter Munk Cardiac Center, University  
of Toronto**