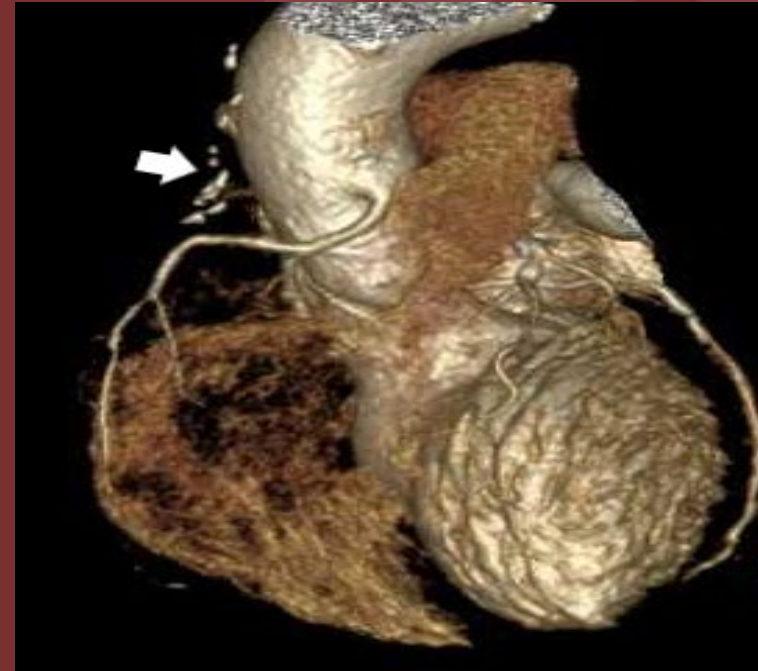
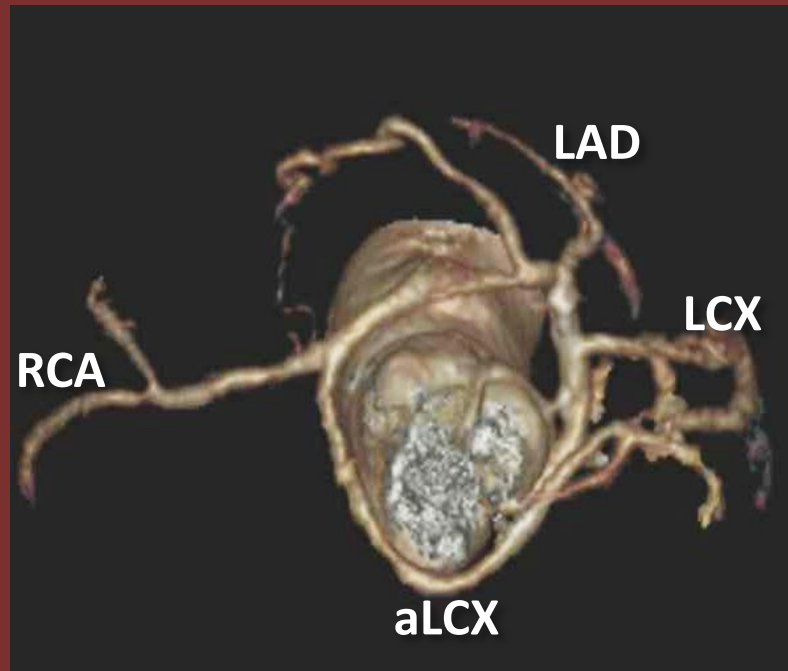


The 50th Anniversary

Fantastic Cases In Cardiovascular Imaging. Case 30
History: 57-year-old woman with prior bypass surgery
(RIMA-RCA) presented with chest pain



Left: The right coronary artery (RCA) has a malignant course and give off an anomalous circumflex artery (aLCX). Right: White arrow point toward surgical clip of occluded internal mammary artery graft to RCA

Diagnosis: Occluded right internal mammary artery graft to the right coronary artery, which has an anomalous origin and malignant course

Anomalous origin of the right coronary artery is the second most common coronary anomaly; a malignant course can cause chest pain which can be surgically intervened. This patient received a repeat bypass to the right coronary artery using a saphenous vein graft.

Author(s): Tung Nguyen, MD; Sethi Pooja, MD

Institution: Texas Tech University Health Science Center at Lubbock