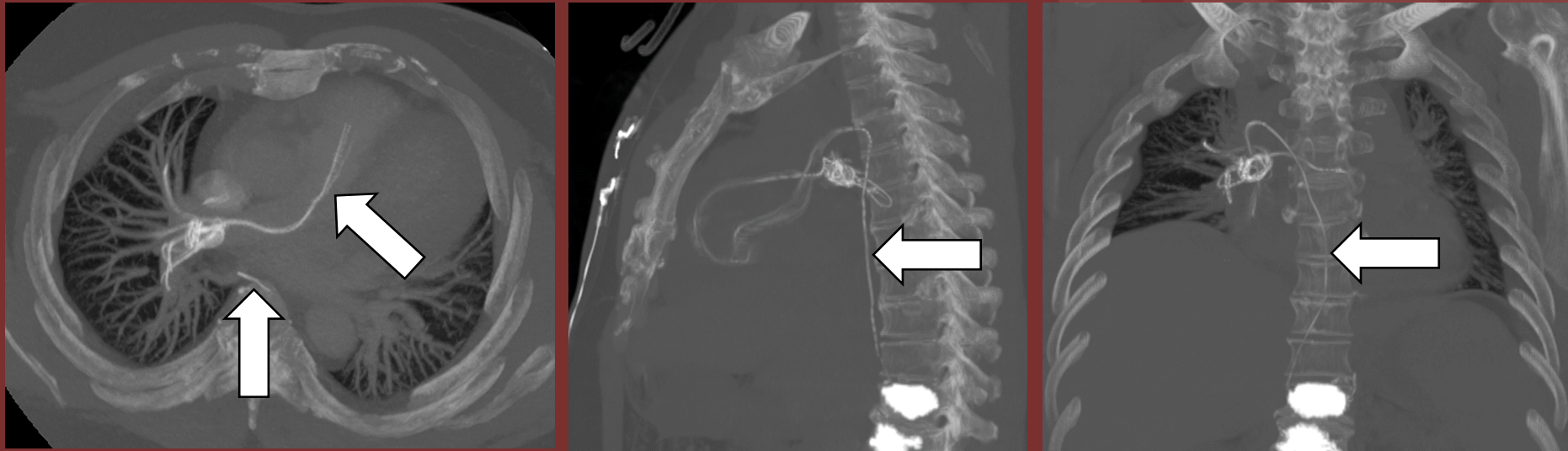


The 50th Anniversary

Fantastic Cases In Cardiovascular Imaging. Case 3

History: 37-year-old female presents with acute shortness of breath following kyphoplasty.



Figure(s): CTA chest axial and multiplanar MIP images reveal fragmented, dense material within the pulmonary and vertebral vasculature.

Diagnosis: Pulmonary cement embolism.

