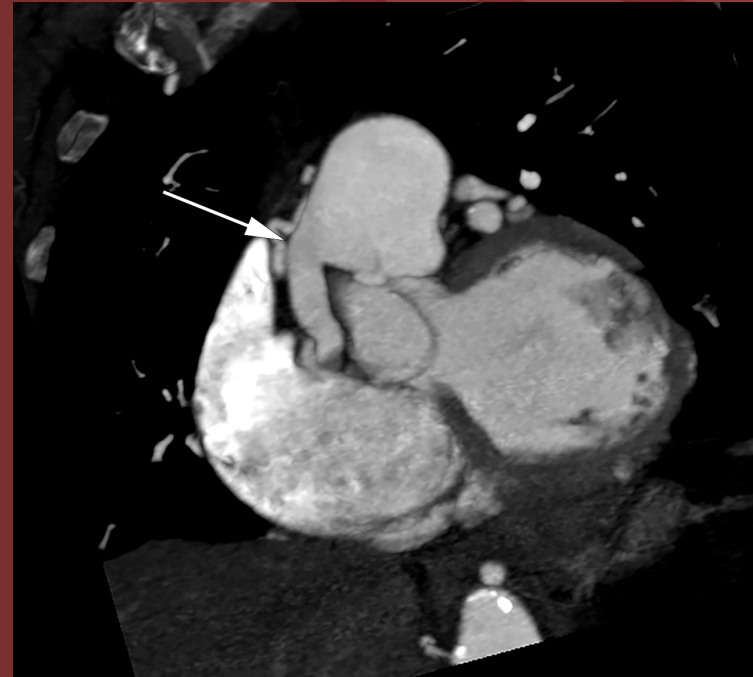
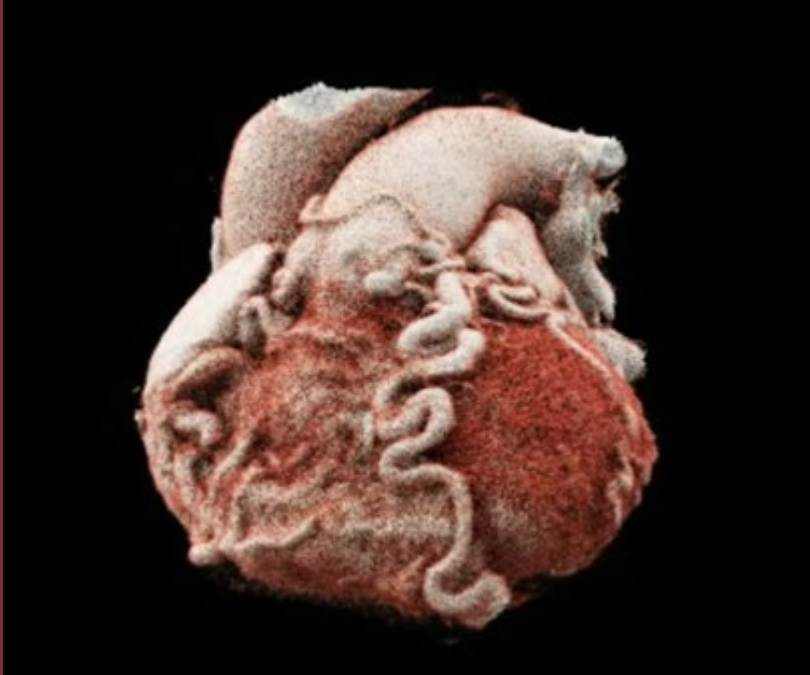

The 50th Anniversary

Fantastic Cases In Cardiovascular Imaging. Case 29

History: 77 year-old female with epicardial collaterals on echocardiogram



Figures: (A) CTA 3D cinematic rendering cine movie demonstrates numerous epicardial arterial collaterals. (B) MIP MPR at the level of the main pulmonary artery demonstrates an abnormal, engorged vessel arising from the main PA (arrow)

Diagnosis: Anomalous origin of the right coronary artery arising from the pulmonary artery (ARCAPA).

Patient with ARCAPA are often asymptomatic. The diagnosis is often made incidentally, compared to patients with anomalous origin of the left coronary artery arising from the pulmonary artery (ALCAPA) who tend to be symptomatic from birth.

Jonathan Revels, DO. University of New Mexico

Sherry Wang, MBBS. University of Utah