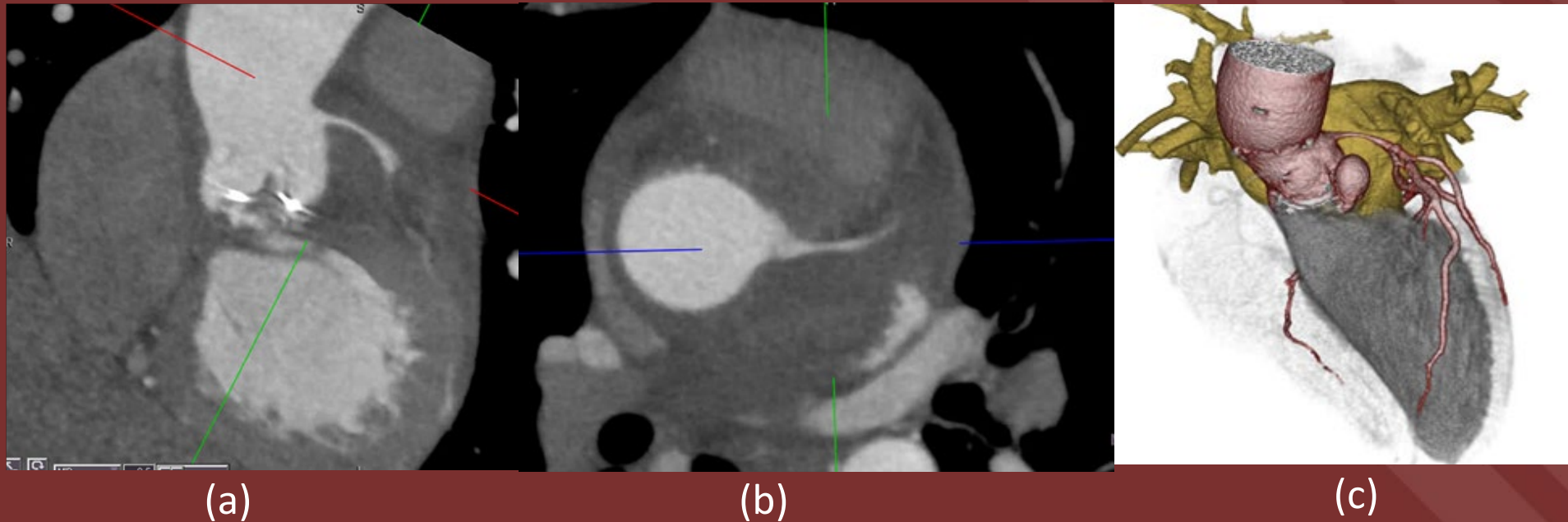


The 50th Anniversary

Fantastic Cases In Cardiovascular Imaging. Case 24

History: Male in his 60s with prior aortic valve replacement presenting with fever and chest pain.



Figures: (a) Prosthetic aortic valve with fat stranding at the aortic root. (b) There is narrowing of the left main coronary artery (c) 3D Volume rendered image showing paravalvular pseudoaneurysm.

Diagnosis: Prosthetic valve endocarditis

Fat stranding at the aortic root, pseudoaneurysm, vegetations, valve dehiscence and fistulization are imaging manifestations of prosthetic valve endocarditis. The paravalvular abscess can compress adjacent structures like coronary arteries.

Sandeep S Hedgire, MD

Massachusetts General Hospital, Boston