

The 50th Anniversary

Fantastic Cases In Cardiovascular Imaging. Case 18

38-year-old man with a 3-month history of night sweats, non-productive cough and weight loss with elevated metanephrine and norepinephrine in 24-hour urine

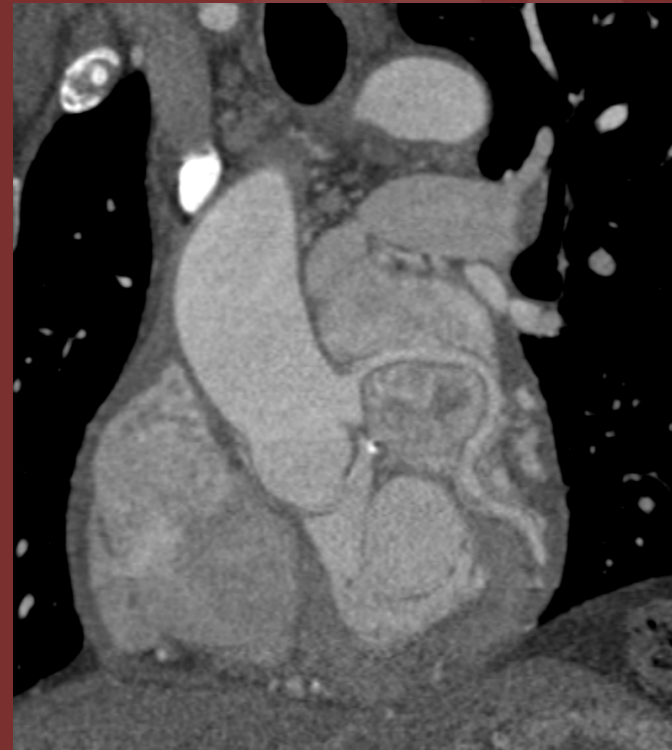
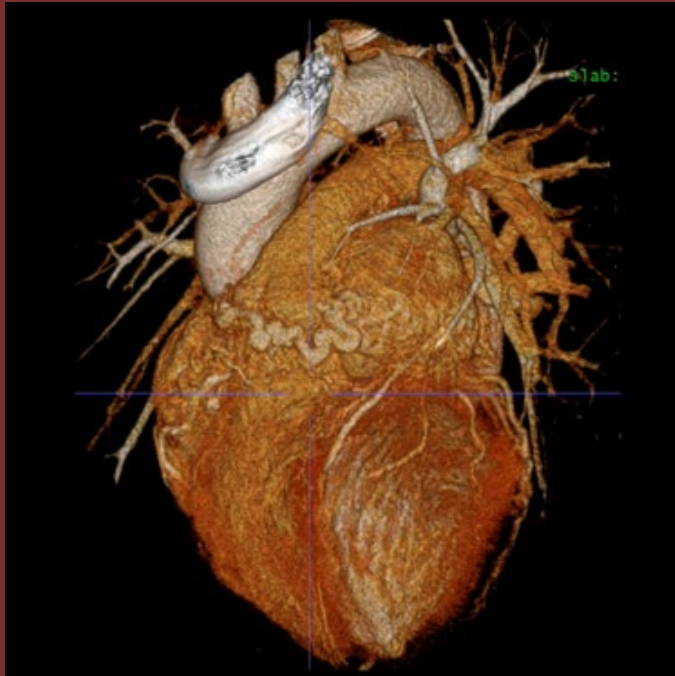

Figure: Cardiac CTA – Slab volume-rendering (A) and MPR (B) views at the level of the aorto-pulmonary groove

Diagnosis: Intrapericardial paraganglioma

Tend to be located in aorto-pulmonary groove close to the left atrium at the level of the paraaortic sympathetic ganglia

Hyperintense on T2-weighted imaging and may have salt and pepper appearance post contrast on MR due to flow void from large intratumoral vessels