

The 50th Anniversary  
Fantastic Cases In Cardiovascular Imaging. Case 17

**History:** 64-year-old woman with LV mass on echo

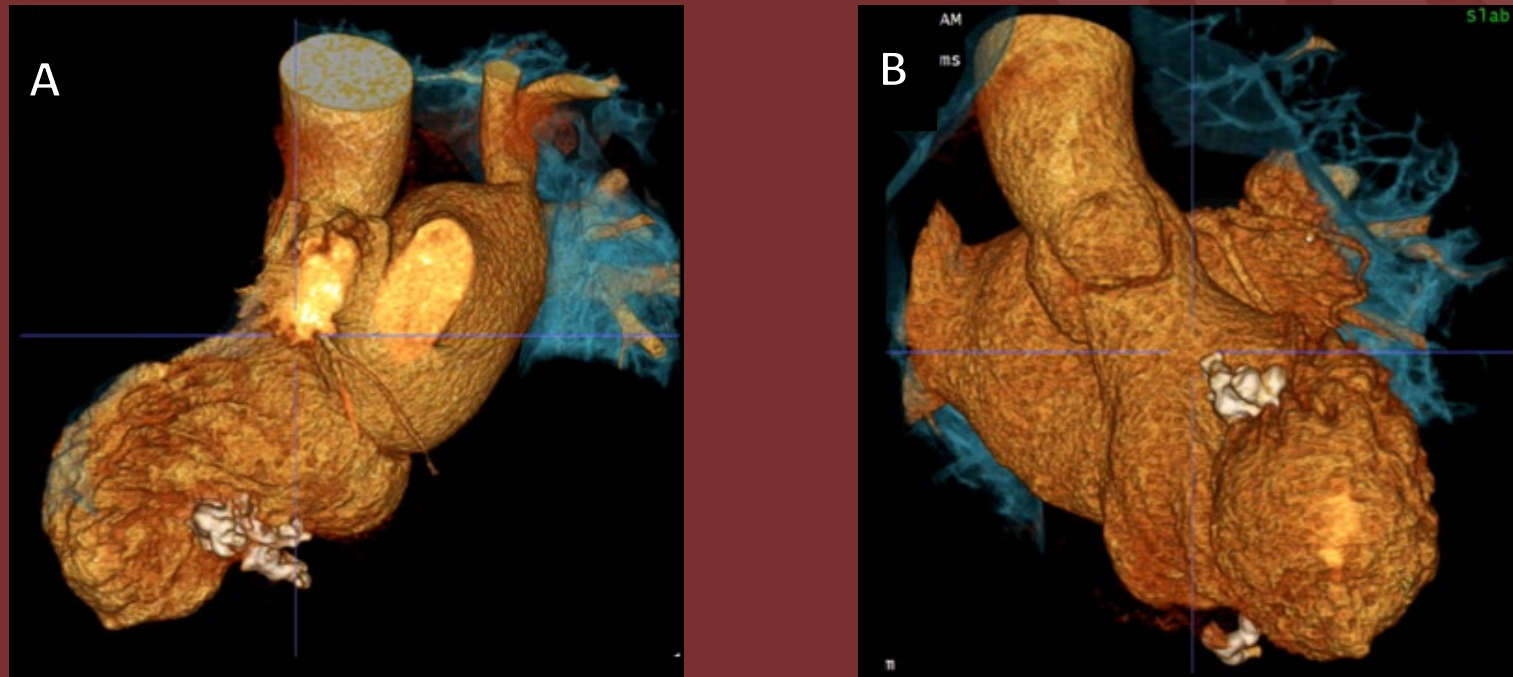


Figure: Cardiac CTA – Slab volume-rendering 3-chamber (A) and short axis views(B)

## Diagnosis: Calcified amorphous tumor of the LV

Rare non-neoplastic cardiac mass that can cause symptoms of obstruction or embolization of calcific fragments (arrow).

