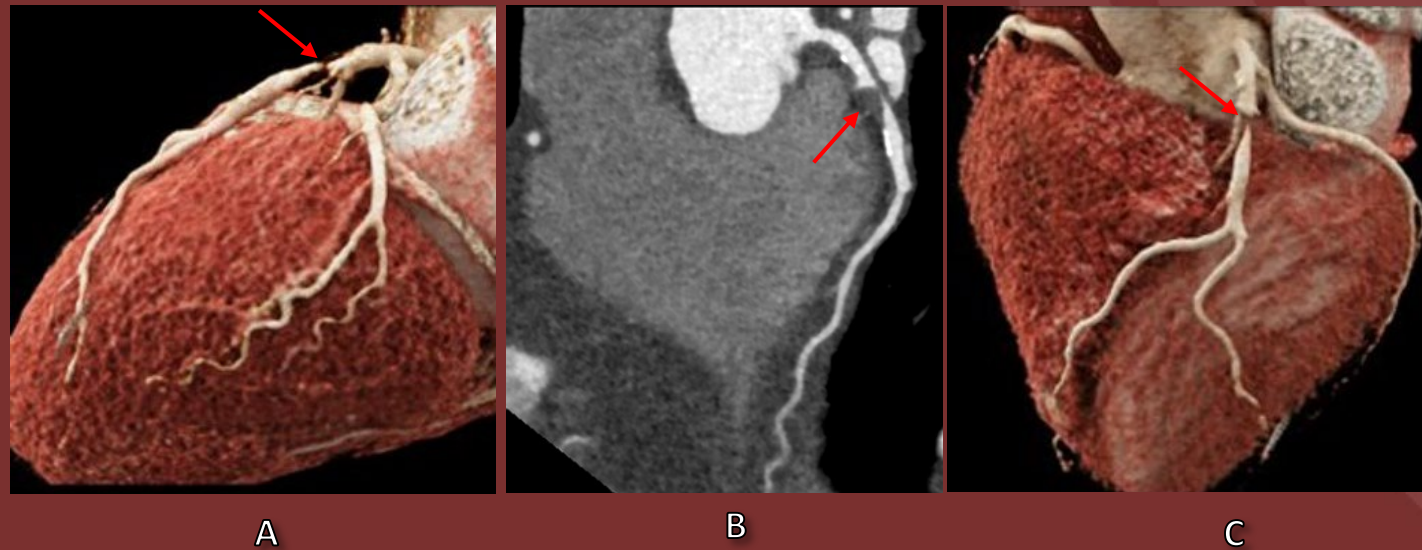


The 50th Anniversary
Fantastic Cases In Cardiovascular Imaging. Case 10

History: 76-year-old male with exertional chest pain.



Figure(s): Cardiac CT coronal view (B) with Cinematic Rendering reconstruction (A, C) show focal noncalcified plaque with severe narrowing of the mid LAD

Diagnosis: Focal high-grade stenosis from noncalcified plaque in the mid LAD.

Noncalcified plaque can result in high-grade stenosis.